



Original Research Article

Efficacy of lid wipes in reducing the incidence of post cataract surgery meibomian gland dysfunction (MGD)

Sonia Bhargav^{1,*}, Tarun Arora²¹Dept. of Ophthalmology, Bhagat Phool Singh Government Medical College for Women, Sonipat, Haryana, India²Centre for Sight Group of Eye Hospitals, New Delhi, India

ARTICLE INFO

Article history:

Received 05-01-2019

Accepted 05-03-2019

Available online 16-06-2020

Keywords:

Dry eye

Meibomian gland dysfunction (MGD)

Lid wipes

Post cataract surgery

ABSTRACT

Objective: The aim of this study was to assess the efficacy of commercially available sterile lid wipes in reducing the incidence of MGD and dry eye after cataract surgery.

Materials and Methods: In this prospective clinical study 40 patients undergoing uneventful cataract surgery were included. They were divided randomly into 2 groups of 20 patients each. The control group was prescribed standard postoperative regimen consisting of topical steroid, antibiotic and NSAID. The study group was prescribed in addition to the above topical regimen, sterile lid wipes for cleaning of lid margin and lashes. The signs and symptoms of all patients were assessed and scoring was done based on severity grading of a structured symptom based Standard Patient Evaluation of Eye Dryness (SPEED) questionnaire, corneal staining, meibum expressibility and meibum quality at preoperative and at postoperative 3 weeks and 6 weeks. The data obtained was analysed statistically.

Results: The SPEED questionnaire, corneal staining, meibum expressibility and meibum quality mean scores worsened statistically significantly in the control group as compared to the study group ($p < 0.001$). In control group, the mean score of all the parameters were statistically significantly worsened at all follow up visits. ($p < 0.001$).

Conclusion: Maintaining lid hygiene with lid wipes in post cataract surgery period is effective in prevention of MGD and dry eye.

© 2020 Published by Innovative Publication. This is an open access article under the CC BY-NC license (<https://creativecommons.org/licenses/by-nc/4.0/>)

1. Introduction

Cataract surgery has been found to induce and aggravate dry eye symptoms. In previous studies, incidence of dry eye after cataract surgery has been reported to be 9.8%-42%.^{1,2} It is the most common cause of ocular morbidity after cataract surgery. It has been demonstrated in various studies that meibomian gland dysfunction (MGD) is one of the important factor leading to tear film instability after cataract surgery.³ In population studies, the incidence of MGD has been reported to vary between 4% and 70% and to be more prevalent in Asian population.^{4,5} It causes not only discomfort to the patient but also gives headaches to the treating doctor who inspite of trying various topical

and oral medications often fails to provide their patients adequate and rapid alleviation of symptoms. Lid hygiene is an important aspect in prevention and treatment of MGD. According to the international workshop on MGD, lid hygiene is regarded as the mainstay of the clinical treatment of MGD.⁶ The aim of this study was to assess the efficacy of commercially available single use sterile lid wipes in reducing incidence of MGD by improving eye lid hygiene in post cataract surgery patients.

2. Materials and Methods

This prospective clinical study was done on 40 eyes of 40 patients registered for cataract surgery from April 2017 to June 2017 at Centre for Sight eye hospital, New Delhi. A written informed consent was obtained from all patients

* Corresponding author.

E-mail address: soniabhargav@yahoo.co.in (S. Bhargav).

after explaining the nature of study. All patients were examined by slit lamp biomicroscope for the presence of MGD signs by assessing corneal staining, meibum expressibility and quality of meibum. Symptoms of dry eye were assessed by a standard dry eye questionnaire, standard patient evaluation of eye dryness (SPEED) questionnaire response. Scoring based on severity was done and those with significant signs and symptoms of dry eye and MGD were excluded from the study. Examination was repeated at 3 weeks and 6 weeks postoperatively.

All patients were operated by the same surgeon and same surgical techniques of clear corneal phacoemulsification by stop and chop method with foldable PCIOL implantation was followed. Only those patients with uneventful surgery were included in the study.

Patients were randomly divided into two groups of 20 patients each- the control and the study group. The control group was prescribed standard post operative topical regimen consisting of prednisolone acetate 1% (started 6 times a day tapered every week over 4 weeks), moxifloxacin 0.5% 4 times a day for 2 weeks, and nepafenac 0.1% 3 times a day for 3 weeks. The patients in the study group were prescribed apart from above regimen, commercially available single use sterile lid wipes for cleaning of lid margin and lashes 3 times a day for 6 weeks. The chief ingredients of the lid wipes are sodium chloride and potassium chloride as electrolytes, sodium citrate dihydrate as emulsifier and purified water as vehicle. The pH of the solution is adjusted to 7.4 using sodium hydroxide. No preservative is added in its formulation.

2.1. Scoring of dry eye

Standard Patient Evaluation of Eye Dryness (SPEED) questionnaire⁷ – A structured dry eye symptom based questionnaire was given to the patients. Patients were evaluated from score of 0 to 28 based upon the response to a questionnaire of 7 questions. Patients with a score of more than 2 were excluded from the study.

Corneal fluorescein staining⁸ Slit-lamp examination with cobalt blue illumination was done after instilling 2% fluorescein dye in the conjunctival sac. Each of the five regions of the cornea: central, superior, temporal, nasal, and inferior, were examined for staining pattern. The grading was done as follows: grade 0- no staining; grade 1- superficial stippling and micro-punctate staining; grade 2- macro-punctate staining with some coalescent areas; and grade 3- numerous coalescent macro-punctate areas. Each of the five regions was graded on a scale from 0 to 3. The scores of the five areas were added to obtain a total score for each eye. Patients with score of more than 0 were excluded in the study.

2.2. Biomicroscopic evaluation of meibomian glands⁹

Meibum expressibility - Digital pressure to the upper and lower tarsus was applied and the degree of pressure required to extrude the meibum was graded as follows: 0- clear meibum easily expressed, 1- cloudy meibum expressed with mild pressure, 2- cloudy meibum expressed with more than moderate pressure and 3- meibum not expressed even with the hard pressure. Patients with score of more than 1 were excluded from the study. Quality of the meibum – Digital pressure applied over lower and upper lid margin to extrude meibum, the quality of which was graded as follows: 0- clear; 1- cloudy; 2- cloudy with granular debris and 3 - thick like toothpaste. Patients with meibum quality score of more than 1 were excluded.

2.3. Statistical analysis

Mean and standard error of mean values of all the parameters in the two groups were calculated and the collected data was analysed using SPSS software (version 13.0, SPSS Inc, Chicago, and II) and compared by paired t-test and continuous values in the same group were analysed using repeated measure ANOVA test. A p- value < 0.001 was considered statistically significant.

3. Results

Forty eyes of forty patients were recruited in the study. There were 11 males and 9 females in control group and 12 females and 8 males in the study group. Mean age in control group was 62.7 ± 4.8 yrs and in study group was 64.0 ± 5.4 yrs.

There was no statistical significance between the preoperative mean scores of SPEED questionnaire, meibum expressibility, meibum quality and corneal staining in both the groups (Table 1).

3.1. SPEED questionnaire

There was statistically significant increase in postoperative mean SPEED scores over preoperative values in both the groups at all postoperative follow-up visits. ($p < 0.001$). The SPEED score was statistically significantly worse in control group as compared to study group at 3 week (11.55 ± 4.58 , 3.2 ± 3.37 , respectively) and 6 weeks postoperatively (15.15 ± 2.0 , 3.75 ± 1.91 , respectively) ($p < 0.001$). Each value represents the mean \pm standard error of the mean (SEM) (Tables 2 and 3) (Figure 1a).

3.2. Corneal staining

The mean corneal staining score was statistically significantly worse in the control group as compared to the study group at postoperative 3 weeks (1.6 ± 1.46 , 0.55 ± 1.00 respectively) and 6 weeks (2.15 ± 1.84 , 0.3 ± 0.92 respectively) ($p < 0.001$ respectively). In the study group,

Table 1: Preoperative mean±SD, p-values of SPEED questionnaire, corneal staining, meibum expressibility, meibum quality scores of control group and study group.

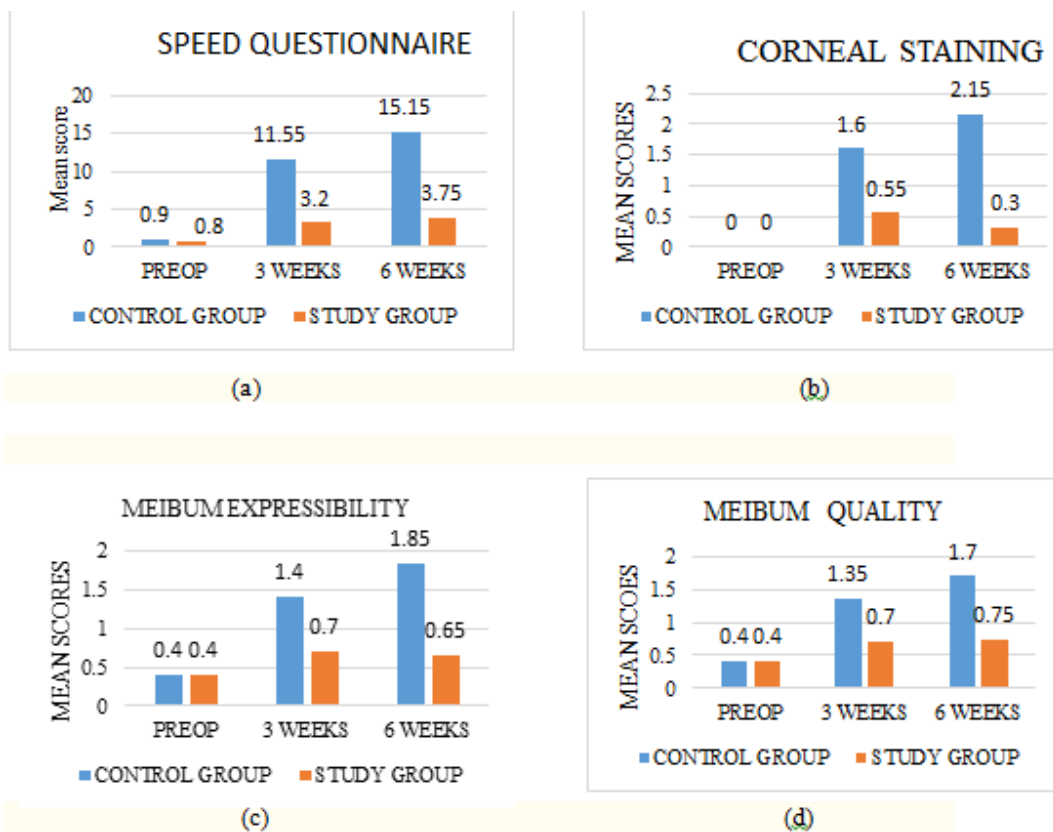
	Control Group	Study Group	p value
SPEED questionnaire	0.90±1.02	0.80±1.00	>0.001
Corneal staining	0±0	0±0	>0.001
Meibum expressibility	0.40±0.50	0.40±0.5	>0.001
Meibum quality	0.40±0.50	0.40±0.50	>0.001

Table 2: Mean± SD and p- values of SPEED questionnaire, corneal staining, meibum expressibility and meibum quality scores of control group and study group at postoperative 3 weeks

	Control Group	Study Group	p-value
SPEED questionnaire	11.55±4.58	3.20±2.37	<.001
Corneal staining	1.60±1.46	0.55±1.00	<.001
Meibum expressibility	1.40±0.75	0.7±0.47	<.001
Meibum quality	1.35±0.74	0.7±0.57	<.001

Table 3: Mean± SD and p- values of SPEED questionnaire, corneal staining, meibum expressibility, meibum quality scores of control group and study group at postoperative 6 weeks

	Control Group	Study Group	p-value
SPEED questionnaire	15.15±4.42	3.75±1.91	<.001
Corneal staining	2.15±1.84	0.30±0.92	<.001
Meibum expressibility	1.85±0.37	0.65±0.49	<.001
Meibum quality	1.70±0.66	0.75±0.64	<.001

**Fig. 1:** Graphs showing mean scores of (a): SPEED questionnaire, (b): corneal staining, (c): Meibum expressibility, (d): Meibum quality in control group and study group at preoperative and at postoperative 3 weeks and 6 weeks.

there was an improvement in mean score at 6 weeks whereas in control group, mean corneal staining score increased in all follow up visits. All postoperative values were statistically significantly higher than their preoperative baseline. ($p < 0.001$) (Tables 2 and 3) (Figure 1b).

3.3. Meibum expressibility

The meibum expressibility mean scores were statistically significantly worse in the control group compared to study group at 3 weeks (1.4 ± 0.75 , 0.7 ± 0.47 , respectively) and at 6 weeks postoperatively (1.85 ± 0.35 , 0.65 ± 0.49 , respectively) ($P < 0.001$, respectively). The mean scores improved marginally at 6 weeks follow up from 3 weeks level in the study group. In both the groups, the postoperative worsening of meibum expressibility mean score over preoperative score was statistically significant. ($p < 0.001$) (Tables 2 and 3) (Figure 1c).

3.4. Meibum quality

The meibum quality was significantly worse in control group than in the study group at 3 weeks (1.35 ± 0.74 , 0.7 ± 0.47 , respectively) and 6 weeks postoperatively (1.70 ± 0.66 , 0.75 ± 0.69 , respectively) ($P < 0.001$, respectively). In both the groups, the postoperative worsening of meibum quality mean score over preoperative score was statistically significant. ($p < 0.001$) (Tables 2 and 3) (Figure 1d)

4. Discussion

The postoperative dry eye, though quite common but is still not clearly understood. Park, et al. in their study observed significant worsening of lid margin abnormality, deterioration of meibum expressibility and quality after cataract surgery.⁴ Kim et al. reported thinning of lipid layer leading to evaporative dry eye after cataract surgery.¹⁰ Alteration in meibum expressibility and tear film breakup time which persist for up to 3 months after surgery suggests direct role of cataract surgery in causing MGD by an obstructive mechanism.¹¹ These studies point towards MGD playing important role in causing dry eye after cataract surgery.

The 2011 International workshop on meibomian gland dysfunction provided the most widely accepted definition of MGD as “MGD is a chronic diffuse abnormality of the meibomian glands characterised by quantitative/qualitative changes in the tear film function leading to symptoms of dry eye and ocular surface disease”.¹² According to Lemp, et al., in general population 86% patients with dry eye have MGD.¹³ Treatment of MGD in some patients is ineffective and symptoms of dry eye and ocular discomfort often persist for many months. Multiple treatment modalities have been suggested for MGD which includes warm lid compresses, oral antibiotics, eyelid hygiene, lid massage, topical cyclosporine and topical N-acetylcysteine.¹⁴

Cause of MGD after cataract surgery is unknown and probably multifactorial. Lid dysfunction because of the use of speculum, decrease in blinking rate because of decreased corneal sensation, ocular surface inflammation may all contribute to MGD. Zhang S D, et al. concluded infective pathology of meibomian gland in MGD and demonstrated significantly higher culture positivity and more complex bacterial profiles in MGD patients than the normal population. Bacterial related cytotoxicity and/or inflammation may contribute to MGD.¹⁵ This reinforces the importance of lid hygiene to prevent meibomian gland infection in postoperative period. More so when it is compromised because of general precautionary measures of water prohibition on the operated eye for 2 weeks postoperatively. The sterile lid wipes could be an effective measure for maintaining lid hygiene after cataract surgery. They help by removing infective microorganisms and inflammatory debris from the meibomian gland orifices. Gullion M, et al. concluded in their study that eye lid hygiene with lid wipes by subjects with anterior blepharitis or MGD significantly decreased their associated symptomatology and increased their ocular comfort.¹⁶ Korb D R, et al. in their study concluded that combination treatment regimen comprising of lid wipes, eye drops and omega 3 supplements resulted in significant improvement in meibomian gland functionality and dry eye symptoms in patients with lipid deficient dry eye.¹⁷

Till date no study has been done to demonstrate the role of lid wipes in preventing MGD post cataract surgery. In our study on post cataract surgery patients, dry eye and MGD signs and symptoms aggravated in both the groups but in the control group patients who were not using lid wipes, they were significantly greater.

5. Conclusion

Post cataract surgery MGD and resulting evaporative dry eye morbidity can be significantly reduced by promoting lid hygiene. Adding commercially available lid wipes to the post cataract surgery regimen is an effective option.

6. Conflict of Interest

None.

7. Source of Funding

None.

References

1. Ishrat S, Nema N, Chandravanshi SCL. Incidence and pattern of dry eye after cataract surgery. *Saudi J Ophthalmol.* 2019;33(1):34–40.
2. Kasetsuwan N, Satitpitakul V, Changul T, Jariyakosol S. Incidence and pattern of dry eye after cataract surgery. *PLoS ONE.* 2013;8(11):e78657. doi:10.1371/journal.pone.0078657.
3. Park Y, Hwang HB, Kim HS. Observation of influence of cataract surgery on the ocular surface. *PLoS ONE.*

- 2016;doi:10.1371/journal.pone.0152460.
4. Schaumberg DA, Nichols JJ, Papas EB, Tong L, Uchino M, Nichols KK. The international workshop on meibomian gland dysfunction: Report of the subcommittee on the epidemiology of, and associated risk factors for MGD. *Invest Ophthalmol Vis Sci.* 2011;52(4):1994–2005.
 5. Maurya RP, Singh VP, Chaudhary S, Roy M, Srivastav T. Prevalence of severe dry eye disease in postmenopausal women in North India: A teaching hospital study. *Indian J Obstet Gynecol Res.* 2019;6(1):94–6.
 6. Geerling G, Tauber J, Baudouin C, Goto E, Matsumoto Y, O'Brien T, et al. The international workshop on meibomian gland dysfunction: report of the subcommittee on management and treatment of meibomian gland dysfunction. *Invest Ophthalmol Vis Sci.* 2011;52(4):2050–64.
 7. Ngo W, Situ P, Keir N, Korb D, Blackie C, Simpson T. Psychometric properties and validation of the standard patient evaluation of eye dryness questionnaire. *Cornea.* 2013;32(9):1204–10.
 8. Lemp MA. Report of the national eye institute/industry workshop on clinical trials in dry eyes. *CLAO J.* 1995;21(4):221–32.
 9. Shimazaki J, Sakata M, Tsubota K. Ocular surface changes and discomfort in patients with meibomian gland dysfunction. *Arch Ophthalmol.* 1995;113(10):1266–70.
 10. Kim JS, Lee H, Choi S, Kim EK, Seo KY, Kim TI. Assessment of the tear film lipid layer thickness after cataract surgery. *Semin Ophthalmol.* 2018;33(2):231–6.
 11. Ameen AE, Majzoub S, Vandermeer G, Pisella PJ. Influence of cataract surgery on Meibomian gland dysfunction. *J Fr Ophthalmol.* 2018;41(6):526–35.
 12. Nelson JD, Shimazaki J, del Castillo JMB, Craig JP, McCulley JP, Den S, et al. The international workshop on meibomian gland dysfunction: report of the definition and classification subcommittee. *Invest Ophthalmol Vis Sci.* 2011;52(4):1930–7.
 13. Lemp MA, Crews LA, Bron AJ, Foulks GN, Sullivan BD. Distribution of aqueous - deficient and evaporative dry eye in a clinic based patient cohort: a retrospective study. *Cornea.* 2012;31:472–8.
 14. Thode AR, Lasky RA. Current and emerging therapeutic strategies for the treatment of meibomian gland dysfunction (MGD). *Drugs.* 2015;75(11):1177–85.
 15. Zhang SD, He JN, Niu TT, Chan CY, Pang CP. Bacteriological profile of ocular surface flora in meibomian gland dysfunction. *Ocular Surface.* 2017;15(2):242–7.
 16. Guillon M, Maissa C, Wong S. Symptomatic relief associated with eye lid hygiene in anterior blepharitis and MGD. *Eye Contact Lens.* 2012;38(5):306–12.
 17. Korb DR, Blackie CA, Finnemore VM, Douglass T. Effect of using a combination of lid wipes, eye drops, and omega-3 supplements on meibomian gland functionality in patients with lipid deficient/evaporative dry eye. *Cornea.* 2015;34(4):407–12.

Author biography

Sonia Bhargav Assistant Professor

Tarun Arora Senior Consultant

Cite this article: Bhargav S, Arora T. Efficacy of lid wipes in reducing the incidence of post cataract surgery meibomian gland dysfunction (MGD). *Indian J Clin Exp Ophthalmol* 2020;6(2):180-184.