



Original Research Article

An autopsy record study of neoplastic lesions of heart in sudden deaths

Smitha M¹, Mallikarjun K Biradar^{2,*}, N S Kamakeri³, Sunilkumar S Biradar⁴¹Dept. of Anatomy, Karnataka Institute of Medical Sciences, Hubli, Karnataka, India²Dept. of Community Medicine, Koppal Institute of Medical Sciences, Koppal, Karnataka, India³Dept. of Pathology, Karnataka Institute of Medical Sciences, Hubli, Karnataka, India⁴Dept. of Forensic Medicine, Karnataka Institute of Medical Sciences, Hubli, Karnataka, India

ARTICLE INFO

Article history:

Received 12-10-2020

Accepted 06-11-2020

Available online 11-01-2021

Keywords:

Leukemia

Melanoma

Sudden death

ABSTRACT

Introduction: World Health Organization (WHO) defines sudden death as "deaths within 24 hours from the onset of the symptoms". It is also defined as death which is sudden, unexpected, clinically unexplained, or otherwise obscure even though there needs to be no unnatural element in their causation. Patients with neoplastic diseases, especially malignancies, are at greatly elevated risk of sudden death, because they may suffer from a variety of neoplasms. Majority of neoplasm-related sudden deaths (NSDs) are caused by neoplasm's affecting critical organs such as the heart and brain.

Objectives: To study the different histomorphological neoplastic lesions of heart in sudden deaths.

Materials and Methods: A total of 1500 hearts were studied. All the sudden deaths which happened in hospital from 1997 to 2016 were included in the study.

Result: In 20 years (1997-2016) nearly 1500 hearts were studied for sudden deaths in our institute. In our autopsy series, only secondary cardiac tumours were seen in 05 cases and caused sudden Ischemic heart disease were reported in 250 (17%) cases and left ventricular hypertrophy in 145(9.60%) cases. Altogether hypertensive heart diseases contributed about 26% of total sudden deaths.

Recommendation: A routine health check up of the people after 40 years along with conducting system is need of the hour.

© This is an open access article distributed under the terms of the Creative Commons Attribution License (<https://creativecommons.org/licenses/by/4.0/>) which permits unrestricted use, distribution, and reproduction in any medium, provided the original author and source are credited.

1. Introduction

World Health Organization (WHO) defines sudden death as "death within 24 hours from the onset of the symptoms". It can also be defined as deaths which are sudden, unexpected, clinically unexplained, or otherwise obscure even though there need to be no unnatural element in their causation.¹ Such a rapid death is often attributed to a cardiac cause. Sudden cardiac death can be prevented if high risk patients are identified and referred to a cardiologist.²

A probable Sudden cardiac death (SCD) is an unexpected death without obvious extracardiac cause that occurred within the previous 24 h. It accounts for 50% of cardiovascular mortality with an estimated annual toll of

300 000 deaths in the USA and 60 000 deaths in the UK. The majorities of SCDs are of ischemic etiology secondary to atherosclerotic coronary artery disease and affect the older section of the population.³ This study will emphasize on finding the causes for sudden deaths.

2. Objective of the Study

1. To study the different histomorphological neoplastic lesions of heart in sudden deaths.

3. Materials and Methods

The present study was conducted at the department of pathology, KIMS, Hubballi, a tertiary teaching hospital located in north Karnataka. All the sudden deaths which

* Corresponding author.

E-mail address: mallubiradar82@gmail.com (M. K. Biradar).

happened in hospital from 1997 to 2016 were included in the study. In 20 years (1997-2016) nearly 1500 hearts were studied for sudden deaths in our institute. All the hearts were dissected according to line of blood flow and sections were stained with Hemotoxyline and Eosin. In the past 20 years hearts of sudden death were examined and majority of hearts were unremarkable both grossly and microscopically, but some of the hearts were showing left ventricular hypertrophy and some of them revealed frank ischemic changes. The microscopic hypertensive changes in kidney were considered as criteria for evidence of hypertension. The cardiac arrhythmias and coronary spasms were attributed for sudden deaths in absence of pathological evidence of ischemic changes.

3.1. Inclusion criteria

Patients who were admitted and died during the course of treatment, their heart specimens were taken for the study.

3.2. Statistical analysis

The data was entered in Microsoft excel 2010 and analyzed using Epi-info 3.5.2. Descriptive statistics for proportions were used.

4. Results

A total of 1500 hearts were studied over a period of 20 years from 1997 to 2016. 37.6% were in the age group of 40-49 years, followed by 26.8% in 30-39 years age group. Only 0.5% of subjects were observed in 10-19 years. Male subjects constituted about 59.2%, while female 40.2% (Table 1). Age ranged from 20-80 years and ischemic heart disease were reported in 250 (17%) cases (Figures 1 and 2) and left ventricular hypertrophy in 145(9.60%) cases (Figure 3) Altogether hypertensive heart diseases contributed about 26% of total sudden deaths. Most common cause of hypertensive heart diseases was atherosclerosis and kidneys show grossly granular appearance on cortical surface benign nephrosclerosis and microscopically hyaline arteriolosclerosis.

Table 1: Age and sex wise distribution of study subjects

Indicators	Number	Percentage
Age(in years)		
10-19	07	0.5
20-29	53	3.6
30-39	401	26.8
40-49	564	37.6
50-59	388	25.7
60 and above	87	5.8
Sex		
Male	889	59.2
Female	611	40.8
Total	1500	100

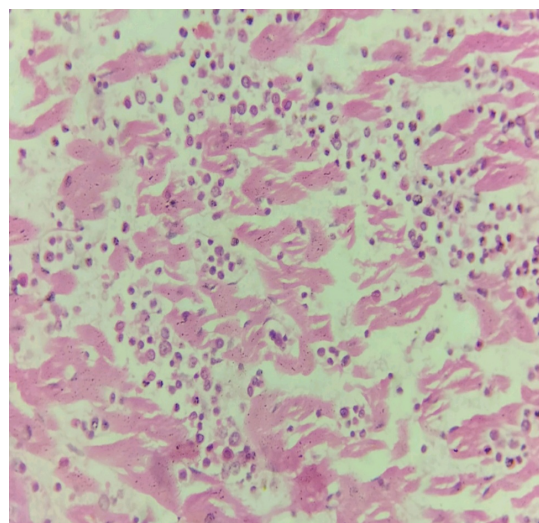


Fig. 1: Section of heart showing chronic myeloid leukemic cells in between the muscle fibres

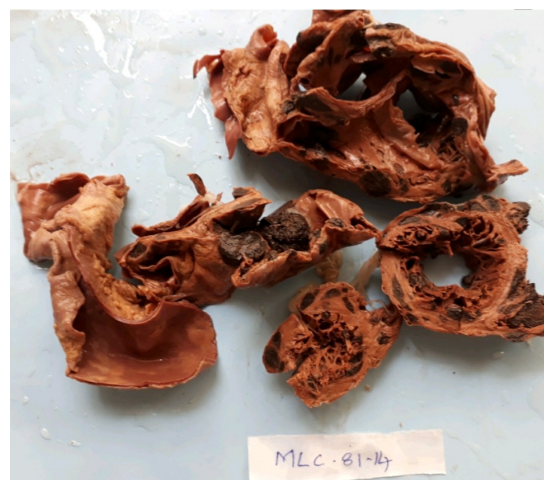

Fig. 2: Specimen of heart with malignant melanoma deposits in heart showing gray brown melanoma masses in between cardiac muscle

5. Discussion

The objective of the study was to find out the causes for sudden deaths. The diagnosis of primary cardiac tumors is frequently challenging. The symptoms associated with most primary cardiac tumors are non-specific, and they often mimic far more commonly encountered disease entities. Furthermore, many tumors are manifested with mild and vague symptoms such that most routine workups will fail to identify the underlying abnormality.

Study by Doolan A in Australia shows that, of 2986 deaths occurred in people aged < or = 35 years, 193 were due to sudden cardiac deaths, and was presumed to be due to primary arrhythmogenic disorders.⁴ Columbus, a noted Pathologist, recorded the first description of a cardiac tumor

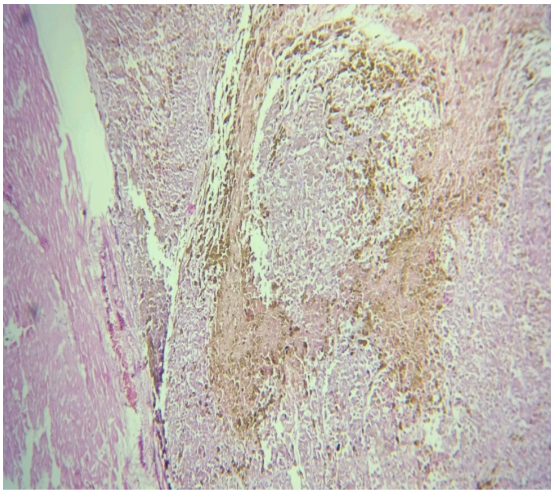


Fig. 3: Section of malignant melanoma deposits in heart showing malignant melanoma cell sheets in between the cardiac muscle bundles

in 1562. Beck C et al. study reported a metastatic cardiac tumor diagnosis in living patient occurred in 1934.⁵ Cohen GU et al. in their study observed that, secondary cardiac tumors are more frequently observed than primary tumors. Clinically, the majority of heart metastases are undetected.⁶ Dawe CJ et al. showed that, the pericardium is often involved by direct extension of intrathoracic tumors particularly in carcinoma of the lung. The heart is more likely to be involved by embolic hematogenous, lymphatic or direct extension.⁸ Infiltration with leukemic cells is reportedly more frequent in acute leukemia than in chronic leukemias were observed in Kirschbaum JD study. Although occasional cases of multiple myeloma have been reported in which deposits of myeloma cells were present in the myocardium in Atkinson K studies.⁷

Grossly, cardiac metastasis from carcinoma are multiple, discrete, small, white firm nodules. Metastases from malignant melanoma are frequently grossly pigmented (Fig2&3). Metastasis may reach the pericardium and myocardium via the blood stream or by a combination of these routes. Direct extension via the vena cava or the pulmonary veins with endocardial implantation has been observed. Although cardiac involvement is rarely evident on gross examination, microscopic infiltration is present in 50% of cases of leukemia and 16% of cases of lymphoma. (fig.1). Which is more frequently associated with amyloid deposition or dystrophic calcification of heart.

6. Conclusion

Totally neoplastic lesions are rare, among them primary are very rare. Here in our study only secondary neoplastic lesions were seen 0.33%. Increased awareness is needed among the population those who are at risk and regular

health checkups after the age of 40 years should be made mandatory so that sudden deaths can be prevented.

7. Source of Funding

Nil.

8. Conflict of Interest

None declared.

9. Ethical Clearance

Not needed as we are presenting this study based on medico-legal autopsy.

10. Acknowledgement

The authors are thankful to the Director, Principal of KIMS, Hubballi for their support. Authors also acknowledge the immense help received from the scholars whose articles are cited and included in references of this manuscript. The authors are also grateful to authors, editors and publishers of all those articles, journals and books from where the literature for this article has been reviewed and discussed.

References

1. WHO International Classification of diseases and related health problems, 10th revision (ICD 10) version for 2010. Available from: apps.who.int/classifications/icd10/browse/2010/en#R96.
2. Kwok KM, Lee KL, Lau CP, Tse HF. Sudden cardiac death: Prevention and treatment. *Hong Kong Med J*. 2003;9:357–62.
3. Patel J, Patel S, Sheppard MN. Benign cardiac tumours associated with sudden death. *Europace*. 2014;16(6):855–60. doi:10.1093/europace/eut378.
4. Doolan A, Semsarian C, Langlois N. Causes of sudden cardiac death in young Australians. *Med J Aust*. 2004;180(3):110–2. doi:10.5694/j.1326-5377.2004.tb05830.x.
5. Beck C. An intrapericardial teratoma and a tumor of the heart both removed intraoperatively. *Ann Surg*. 1942;116:161–74.
6. Cohen GU, Peery TM, Evans JM. Neoplastic invasion of the heart and pericardium. *Ann Int Med*. 1955;42:1238–45.
7. Atkinson K, McElwain TJ, Mackay AM. Myeloma of the heart. *Heart*. 1974;36(3):309–12. doi:10.1136/hrt.36.3.309.

Author biography

Smitha M, Assistant Professor

Mallikarjun K Biradar, Associate Professor

N S Kamakeri, Professor

Sunilkumar S Biradar, Professor

Cite this article: Smitha M, Biradar MK, Kamakeri NS, Biradar SS. An autopsy record study of neoplastic lesions of heart in sudden deaths. *Indian J Clin Anat Physiol* 2020;7(4):331-333.