



Case Report

Anesthetic management of a known case of pemphigus vulgaris with diabetes mellitus posted for surgery

Namrata Kochhar¹, Ritwik Chakraborty^{1,*}

¹Dept. of Anaesthesia, Lal Bahadur Shastri Hospital, New Delhi, India



ARTICLE INFO

Article history:

Received 27-05-2020

Accepted 24-07-2020

Available online 25-11-2020

Keywords:

Pemphigus vulgaris

Spinal anesthesia

ABSTRACT

80 yr old diabetic female known case of pemphigus vulgaris, got admitted to our hospital with relapse of fresh lesions. During her hospital stay she fell down in the washroom and developed fracture in inter-trochanteric region of left femur for which surgery was planned. She had pancytopenia, low hemoglobin level, low platelet count and deranged blood sugar levels. After optimization she was planned for surgery under spinal anesthesia. Special care was taken during transfer, positioning, placement of intravenous lines and monitors. She was premedicated with intravenous steroids. Part was painted gently with chlorhexidine & spinal anesthesia was administered using hyperbaric bupivacaine with a 26 gauge Quincke's needle taking care not to puncture the blisters and papules. Pressure points were adequately padded. Intra-operative hemodynamics were stable. Post-operatively, care was taken for the existing lesions along with special care to prevent the development of fresh lesions.

© This is an open access article distributed under the terms of the Creative Commons Attribution License (<https://creativecommons.org/licenses/by/4.0/>) which permits unrestricted use, distribution, and reproduction in any medium, provided the original author and source are credited.

1. Introduction

Pemphigus vulgaris is an autoimmune disease characterized by bullous lesions of skin and mucous membrane.¹ Patients with pemphigus vulgaris can present with numerous issues which can complicate anesthetic management. Placement of intravenous lines and monitors require careful inspection of the site so as to prevent injury to skin lesions. As the patients are being treated with immunosuppressants and high dose of steroids they may have side effects like bone marrow depression and Addisonian crisis, posing a challenge to the anesthesiologist. Lesions in the airway can make airway instrumentation difficult and risky. Regional anesthesia is hence commonly chosen in these patients whenever possible. Geriatric patients with this disease may have other co-morbidities which can complicate intra-operative management.

2. Case Study

80 year old female, known diabetic for 20 years on insulin therapy and Pemphigus Vulgaris for 10 years on oral steroids got admitted to our hospital with relapse of fresh skin lesions. Dermatology consultation was sought after which she received Cyclophosphamide therapy. While being managed in the hospital, she fell down in the washroom and developed fracture in inter-trochanteric region of left femur.

The patient was emaciated; vitals were normal and systemic examinations were within normal limits. There were blisters and papules on the upper limb, chest, abdomen and lower limb. The skin overlying the back had blisters all over except on the skin overlying the L3-L4 inter vertebral space, however there were no active lesions on the skin of the back. There was no deformity of the spine. Airway examination revealed Mallampati Grade I, blisters on the oral mucosa and poor oral hygiene, thyromental distance was 6 centimeters, mouth opening was 3 fingers and she had normal range of neck movement. Blood examination revealed low hemoglobin level, low total white blood cell count (TLC) and low platelet count, peripheral

* Corresponding author.

E-mail address: ritwikchakraborty29@gmail.com (R. Chakraborty).

smear revealed pancytopenia, fasting & post-prandial blood glucose levels were high. Patient was administered GCSF (Granulocyte colony stimulating factor) injections 300 mcg subcutaneously once daily for 3 days in view of low TLC count. After the 3 injections her TLC count became normal. In view of low hemoglobin 2 units of packed red blood cells were transfused. Patient also received 4 units of platelet concentrates for low platelet count after which platelet count reached acceptable level for anesthesia and surgery. Endocrinology advice regarding insulin therapy for managing deranged blood sugar levels was followed. After optimization she was accepted for open reduction & internal fixation of left femur under subarachnoid block. Patient was kept nil per oral since midnight, tablet alprazolam was prescribed at dose of 0.25 mg at midnight, high risk consent was taken, morning dose of insulin was skipped. On the morning of surgery fasting blood sugar and electrolytes were within normal limits, urine was negative for ketones.

While shifting to the operation theatre precaution were taken not to injure the blisters and papules. Blood pressure cuff, electrocardiogram leads & pulse oxymeter were attached in blister free area. Vitals were within normal limits. A 20 gauge cannula was inserted on the dorsum of right hand as the skin in that region was free of blisters and papules; while fixing the cannula with a transparent cannula fixing adequate care was taken not to overlap neighboring blisters. Pre-loading was done, the patient was pre-medicated with injection dexamethasone 6 mg intravenous bolus dose.

The procedure of spinal anesthesia was explained to the patient and she was shifted to left lateral position after which the pressure points and blisters were padded. Taking all aseptic measures her back was painted gently with chlorhexidine and draped. L3-L4 inter vertebral space was felt & 26 gauge spinal needle was inserted without giving local anesthesia in order to avoid sloughing of skin. After free flow of CSF 2.4 ml of 0.5 % heavy bupivacaine mixed with 10 micrograms of fentanyl were injected and the patient was made supine and padded properly at the pressure points and skin lesions. There was complete motor blockade of the lower limbs and sensory block assessed by sensory response to cold saline was up to T6 level.

Intra-operative monitoring was done in the form of non-invasive blood pressure, heart rate, oxygen saturation, electrocardiography, end-tidal carbon dioxide concentration, skin surface temperature, blood sugar levels and blood loss. Appropriate care of the skin lesions was taken during traction & counter-traction. Her intra-operative hemodynamic status remained stable and hourly sugar levels were within normal limits. The surgery was uneventful and lasted for 2 hours; blood loss was below the maximum allowable blood loss. Before shifting out her vitals were normal, consciousness was intact and her reflexes were normal.

Post-operatively, endocrine opinion was followed for post-operative blood sugar management. The patient was pain free for 5 hrs after surgery when she started having mild pain for which she was administered paracetamol 1 gram intravenously. She did not have nausea, vomiting, drowsiness, pruritus or any other complaints in the post-operative period. The patient was discharged after 2 days after ensuring that no new lesions had developed.

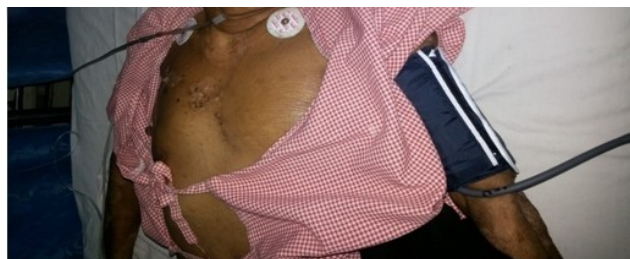


Fig. 1:

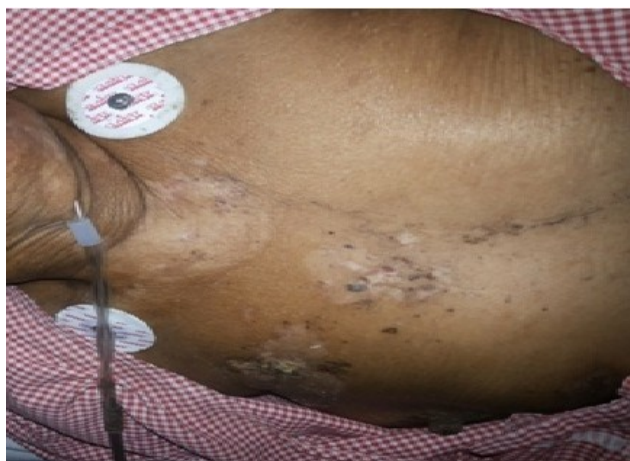

Fig. 2:

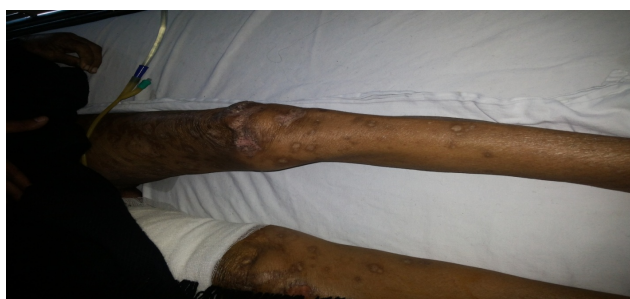

Fig. 3: 3

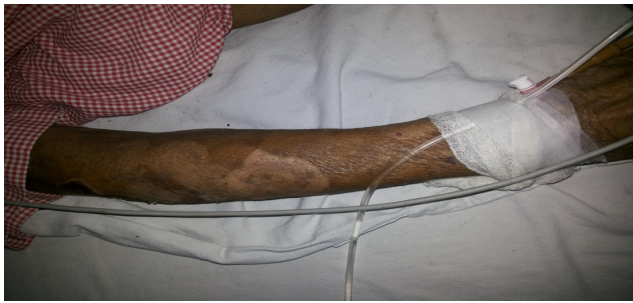

Fig. 4:

3. Discussion

Pemphigus vulgaris is an autoimmune disorder characterized by vesicubullous lesions & blisters involving the skin and mucous membranes. The clinically characteristic lesions are the presence of flaccid weeping lesions which leave large denuded areas. Blisters rupture very easily and crusting ensues. Oral cavity, pharynx and larynx may also be involved. During pre-anesthetic checkup detailed history of the disease and the treatment of it should be documented including the dose and duration of steroid therapy and immunosuppressant. Careful examination of the site, staging and extent of lesion is required. Perioral region should also be inspected as perioral scarring from previous lesions can limit mouth opening. Inspection of the oral cavity can reveal ulceration, edema and risk of bleeding from existing lesions. Mouth opening and neck movement may be restricted from painful ulcerations. Investigations should include complete blood count (to check for bone marrow depression as an effect of immunosuppressant), kidney function test (to check for side effects of steroids) and serum electrolytes as there can be water and electrolytes loss from raw areas.² Tracheal intubation is difficult in these patients because of possible ulcerations and edema from pre-existing lesions in the glottis.

In the operation theatre care should be taken during positioning and transport. The intravenous lines should be placed at skin free of any lesions. Gauze pieces soaked in saline and hydrocortisone should be placed on the arm before tying the BP cuff and pressure points should be padded to avoid development of new lesions (Kobnoer's phenomenon). Electrocardiogram leads should be placed at skin free of lesions. These patients should be adequately premedicated with corticosteroids to prevent Addisonian crisis arising from adrenal insufficiency in these steroid dependent patients. At the time of administering subarachnoid block strict asepsis should be maintained and part should be gently prepared to avoid sloughing of skin lesions. Skin areas free of lesions should be chosen for performing lumbar puncture and skin infiltration with local anesthetic should be avoided.² Smaller gauge intrathecal needle should be used to minimize trauma. Intrathecal

morphine has been successfully used in patients with pemphigus vulgaris.³ For patients with Diabetes Mellitus use of bupivacaine mixed with fentanyl is associated with less hemodynamic consequences.

Thiopentone should be avoided as it causes porphyrias in bullous skin lesions.⁴ Propofol is beneficial as it prevents pruritis, nausea and vomiting by depressing the central nervous system. Neuraxial opioids should be avoided as it causes pruritus resulting in itching leading to the development of Kobnoer's phenomenon and is associated with nausea and vomiting.⁵

Oropharyngeal mucosal lesions usually occur in 50%–80% of these patients. Bag and mask ventilation should be gentle, facial lesions should be covered with hydrocortisone cream and soft cotton sponges before placing the face mask. Face mask should be held without pressure which can result in delayed preoxygenation. Airway instrumentation is potentially hazardous in such patients in view of risk of ulceration, edema, and bleeding from these pre-existing bulla. Cicatricial laryngeal lesions causing severe airway obstruction has been reported.⁶ Whenever general anesthesia requiring a secure airway (intubation/laryngeal airway) is unavoidable, all protective measures shall be ensued. In patients with documented oral lesions putting in a tracheal tube is a safer technique over LMA for the risk of bleeding from intraoral lesions and aspiration. Suctioning should be done gently.

Post-operatively care should be taken to ensure adequate hydration & oxygenation of the patient and to avoid development of new lesions.

4. Conclusion

Pemphigus Vulgaris is an autoimmune disease of skin, the treatment options can have impact on major organ systems of the body. Our patient had pancytopenia as a result of the immunosuppressant therapy and deranged blood sugar levels which were optimized before surgery. As these patients are steroid dependent they can develop Addisonian crisis in the perioperative period, hence we premedicated our patients with steroids. Administration of general anesthesia could be dangerous in these patients as hazardous complications could arise during bag & mask ventilation and tracheal intubation due to trauma and bleeding of the oral lesions. Spinal anesthesia with a smaller gauge spinal needle was selected as our anesthetic technique as it was a lower limb surgery and the site of administration of spinal anesthesia was free of skin lesions. In order to avoid Kobnoer's phenomenon utmost care needs to be taken in the perioperative period, hence pressure points & skin lesions were adequately padded and care was taken during patient transport, positioning, application of monitors, while inserting intravenous lines and administration of regional anesthesia to avoid trauma to the skin lesions. Post-operatively fresh lesions can develop;

hence patient care was extended into the postoperative period while ensuring adequate hydration, oxygenation, post-operative pain management and post-operative blood sugar management of the patient.

5. Source of Funding

None.

6. Conflict of Interest

The authors declare that there is no conflict of interest.

References

1. Smith GB, Shribman AJ. Anaesthesia and severe skin disease. *Anaesth.* 1984;39(5):443–55. doi:10.1111/j.1365-2044.1984.tb07313.x.
2. Abouleish EI, Ellias MA, Lopez M, Hebert AA. Spinal anesthesia for cesarean section in a case of Pemphigus foliaceus. *Anesth Analg.* 1997;84:449–50.
3. Gsan F, Meilan ML, Roses R, Olivera G. Regional anaesthesia in pemphigus vulgaris. *Anaesth.* 1992;47(1):74. doi:10.1111/j.1365-2044.1992.tb01970.x.
4. Patridge BL. Skin and bone disorder. In: Benumoff JL, editor. *Anaesthesia and uncommon diseases*. Philadelphia: W.B. Saunders; 1998. p. 421–8.
5. Mahajan R, Grover VK. Neuraxial Opioids and Koebner Phenomenon: Implications for Anesthesiologists. *Anesthesiol.* 2003;99(1):229–30. doi:10.1097/00000542-200307000-00036.
6. Jeyaram C, Torda TA. Anesthetic Management of Cholecystectomy in a Patient with Buccal Pemphigus. *Anesthesiol.* 1974;40(6):600–1. doi:10.1097/00000542-197406000-00019.

Author biography

Namrata Kochhar, Senior Resident

Ritwik Chakraborty, Senior Resident

Cite this article: Kochhar N, Chakraborty R. Anesthetic management of a known case of pemphigus vulgaris with diabetes mellitus posted for surgery. *Indian J Clin Anaesth* 2020;7(4):703-706.