



Case Report

Central airway obstruction in a patient of tracheobronchial carcinoma: A case report

Amit Bodkhe^{1,*}, Hemant Bhirud¹, Sanjay Upadhye¹, Meghana Nadkarni¹, Chitra Pitale¹, Avanti Purohit¹

¹Dept. of Anaesthesiology, Asian Cancer Institute, Mumbai, Maharashtra, India



ARTICLE INFO

Article history:

Received 12-02-2020

Accepted 10-01-2020

Available online 03-06-2020

Keywords:

Endobronchial tumour embolism

Tracheobronchial tumour

One lung anaesthesia

Respiratory distress

ABSTRACT

Surgery is one of the curative treatments for patients with tracheobronchial tumours. And endoscopic debridement is one of the palliative therapies for unresectable tumour. Respiratory distress is the commonest complication that can occur in both the procedures. We present the case of 25 year old patient of adenoid cystic carcinoma of lower trachea and left bronchus. He had respiratory distress after induction of anaesthesia which was managed successfully with one lung anaesthesia with single lumen endobronchial tube. It was inoperable tumour and after endobronchial debridement he had episode of tumour embolism to opposite bronchus causing respiratory distress. This was detected immediately and managed successfully with flexible bronchoscopy.

© 2020 Published by Innovative Publication. This is an open access article under the CC BY-NC license (<https://creativecommons.org/licenses/by-nc/4.0/>)

1. Introduction

Tracheobronchial resection surgery or endobronchial debridement procedures are very challenging to the Anaesthesiologist as an abnormal airway is shared with the operative team. Endobronchial tumour embolism is a rare cause of acute central airway obstruction and the outcome is frequently fatal.¹ We present a case of tracheobronchial mass where we encountered respiratory distress after induction of Anaesthesia. Later he underwent endobronchial debridement as tumour mass was inoperable. Post procedure he had episode of resected mass embolism to contralateral bronchus causing respiratory distress. This case report describes the various anaesthetic issues involved which were managed successfully.

2. Case Report

25 year old male admitted with complaint of cough. He had no comorbidity and diagnosed with adenoid cystic carcinoma of lower trachea and left bronchus with

extraluminal spread. He had received radiation therapy for the tumour. On examination he had reduced air entry on left side of chest. His breath holding time was 30 seconds. On chest X-ray left bronchus was not visualised but there was no underlying collapse (Figure 1). Spirometry revealed fixed intrathoracic obstruction. FEV1 was 1.6 Litre with poor response to bronchodilator therapy. CT thorax showed mass at lower trachea extending upto left bronchus (Figure 2). This was confirmed on bronchoscopy (Figure 3). His blood investigations were normal.

He was posted for tracheobronchial resection and reconstruction surgery with laryngeal drop and median sternotomy approach. Thoracic epidural catheter was inserted at T3-T4 level with 18G Touhy needle. He was induced with IV Glycopyrrolate 0.2 mg, IV Midazolam 2mg, IV Fentanyl 150 mcg and IV Propofol 150 mg. After confirming adequate ventilation, trachea was intubated with 7 mm endotracheal tube (ET) after IV Succinylcholine 100 mg. Immediately after connecting to ventilator, high airway pressure was noted. This was compromising the inspired tidal volume. On auscultation, there was reduced air entry on right side and it was absent on left side of the chest.

* Corresponding author.

E-mail address: dramitbodkhe123@yahoo.co.in (A. Bodkhe).

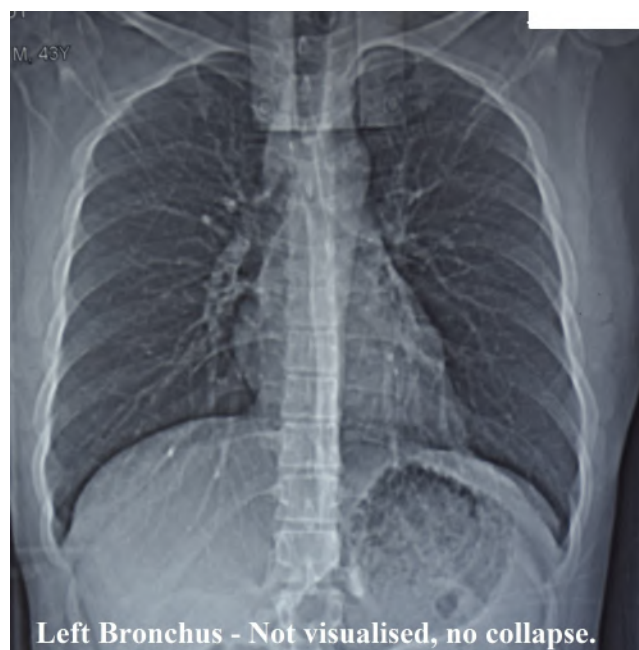

Fig. 1:

We presumed, airway compromise secondary to loss of tone due to muscle relaxation. Bronchoscopy was done to confirm ET placement which revealed the tip above the tracheal mass but there was near complete obstruction of the lower tracheal lumen with tumour mass (Figure 4). There was small space on right side, from where bronchoscope was passed beyond the tracheal mass with little difficulty. This case scenario was discussed with the surgical team. It was not a friable tumour by histology. So in view of oxygen desaturation and anticipated rise in end tidal carbon dioxide, right bronchial intubation was done by sliding the ET over bronchoscope without any resistance. With this maneuver, ventilation was improved. As he was maintaining well on one lung ventilation (OLV), surgery was proceeded with laryngeal drop through neck incision. Right femoral vein and right radial artery were cannulated for intravenous access and invasive BP monitoring respectively. After laryngeal drop he underwent right thoracotomy for resection and reconstruction of trachea. The tumour was inoperable because there was no free bronchial margin available for anastomosis. He was ventilated overnight in ICU. Before extubation ET was withdrawn above tumour mass. There was no collapse of left lung on chest X-ray and extubated uneventfully.

After three days he underwent debulking of the tumour with diode LASER fulguration with multiple passes under GA without muscle relaxation. He was intubated with adequate dosage of intravenous Glycopyrrolate, Midazolam, Fentanyl and Propofol with 7.0mm ET. All necessary precautions were taken for LASER procedure. Eyes were taped and covered with saline soaked pads.

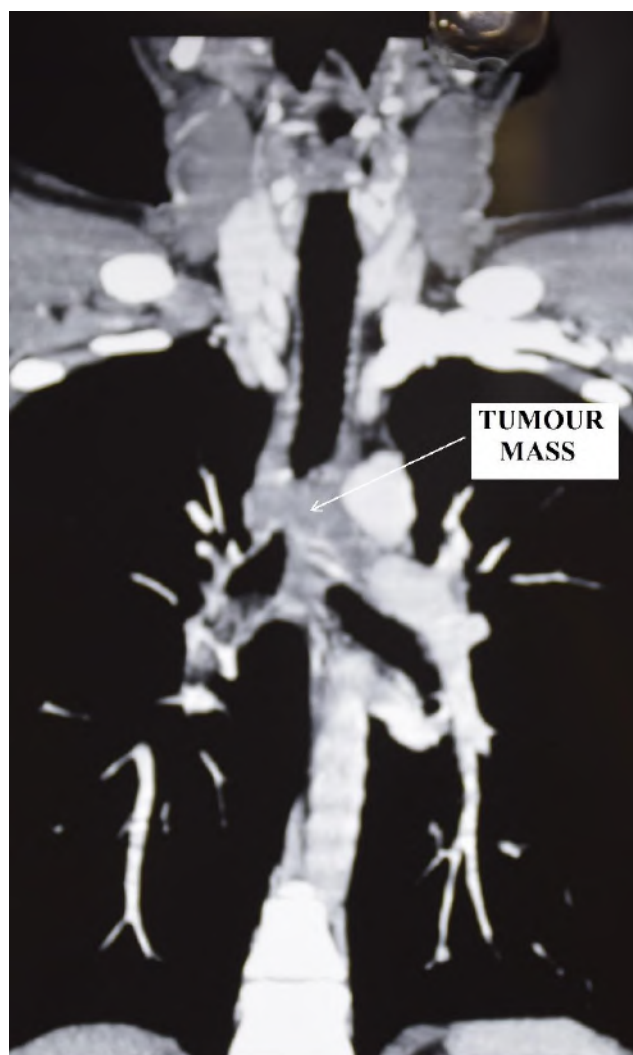


Fig. 2:

LASER protected eyeglasses were used by operating room staff. Tip of ET was above tumour mass which was confirmed on bronchoscopy. The procedure was done with alternate intermittent apnea technique and assisted ventilation. Tumour necrosis was observed and removed in piecemeal with the diode LASER fibre, through flexible bronchoscope. LASER fulguration was done with multiple passes. Left bronchial opening was widened with this procedure. He was extubated on table and shifted to ICU with spontaneous respiration. Within one hour he had an acute episode of respiratory distress. Because of decreasing Oxygen saturation his trachea was intubated with 6.5 mm ET. There was high resistance to bag ventilation. This was confirmed on ventilator which had shown high airway pressure. Right bronchial intubation was successfully attempted without flexible bronchoscope. Check bronchoscopy was done as ventilation was not improved. There was embolic mass causing obstruction in

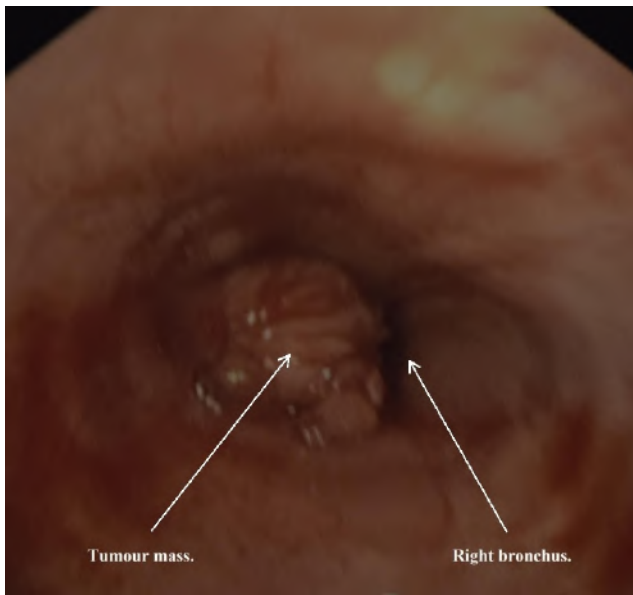


Fig. 3:

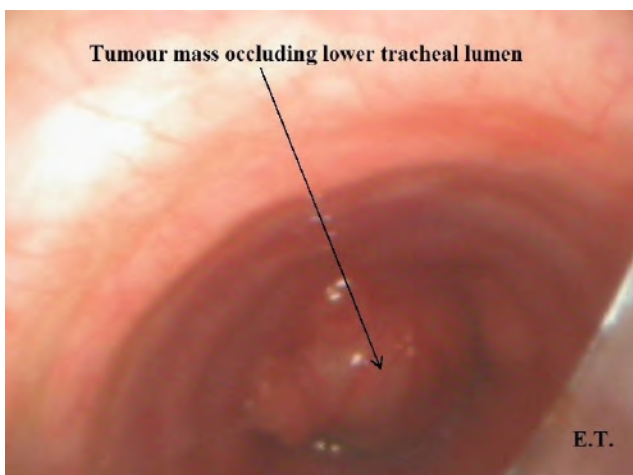


Fig. 4:

the right bronchus just below the ET tip. It was successfully extracted with flexible bronchoscope. Ventilation was improved and later ET was pulled back with its tip just above the tumour mass. Left sided bronchoscopy was done which was normal. He was extubated next day uneventfully. Second setting of diode LASER fulguration was done uneventfully after three days with same technique. Next day he had again sudden respiratory distress in ward. He became apnoeic and lost consciousness immediately. He was intubated with 6.5mm ET. During this he suffered cardiac arrest. Despite doing all standard resuscitation attempt he could not be revived.

3. Discussion

Primary tumors of the trachea are rare. For tracheal tumour complete resection is the standard treatment and in unresectable tumour alternative therapies such as endoscopic debriement, internal stenting, and local or external radiotherapy may provide reasonable palliation.² Maintaining oxygenation and ventilation is a cornerstone of any airway surgery. The ability to provide adequate ventilation throughout the perioperative period is a major predictor for better outcome.³ In the present case report the tumor had extraluminal extension so preoperative LASER debriement was not considered. The patient was not in stridor preoperatively so we used short acting muscle relaxant after confirming adequate ventilation. After its use, the loss of tone could have contributed to near complete obstruction of lower tracheal lumen and respiratory distress. A variety of methods for providing adequate oxygenation and carbon dioxide elimination have been used during tracheal resection.⁴ These include, standard orotracheal intubation, insertion of a tube into the opened trachea distal to the area of re-section, high frequency jet ventilation (HFJV) through the stenotic area, low frequency jet ventilation for stent insertion, high frequency positive pressure ventilation (HFPPV), and cardiopulmonary bypass specially when left thoracotomy approach is used.^{5,6} We used standard orotracheal intubation which did not work because of the distal obstruction. So we aimed to pass the ET beyond the obstruction. The tumour mass was involving distal trachea so there was no margin to secure the ET to ventilate both the bronchi. Right endobronchial intubation was attempted as a rescue method to improve the ventilation. This worked out successfully so we proceeded with the surgery with the back up plan of independent lung ventilation (ILV) through cross field intubation, if needed. ILV is one of the ventilatory strategy use in such scenario especially post tracheal transection.⁷ Left endobronchial intubation with separate ET could have been easily achieved post median sternotomy and so the ILV. Though it was not needed and it turned out to be inoperable tumour. In our case, the successful outcome could have been because of the young age with good cardiorespiratory function. In such scenario OLV with endobronchial ET can be used as one of the ventilatory strategy in lower tracheal tumour resection, when other modalities can not be used for technically reason.

Endoscopic clearance of endotracheal tumor may be performed for palliation in otherwise inoperable patients or as a means of maintaining airway patency until subsequent definitive surgical resection can be performed. The earliest reported method of endobronchial tumor management was simple mechanical removal.⁸ A diode LASER is used to photocoagulate and destroy the intraluminal tumour mass.⁹ Endobronchial tumour embolism is rare, has primarily been described with lung surgery and is difficult to manage

in the acute setting.¹⁰ Adenoid cystic carcinoma is not a friable tumour but life-threatening endobronchial tumour embolism may occur more frequently in patients with a centrally located, intrabronchial, polypoid mass and most reported cases of embolic tumor obstruction were squamous cell carcinoma or carcinosarcomas, which are known to be friable tumors.^{11,12} Awareness of this condition will help in early suspicion of tumour embolism in case of respiratory distress. In our case, as respiratory distress occurred immediately after extubation so we suspected tumour mass itself or tumour embolus obstructing the airway. Conventional tracheal intubation didn't improve the ventilation so immediately right endobronchial intubation was done with smaller ET (6.5mm), considering the intraoperative experience. When bronchial obstruction by embolic tumor mass occurred, the best choice of treatment is depend on the process of surgery or interventional procedure, patient position, size and number of embolic mass, site of obstruction and method of maintaining one-lung ventilation. Fortunately, in our case tumour plug was removed from right main bronchus with flexible bronchoscope. Flexible bronchoscopy is often ineffective in tumor embolus retrieval.^[13] In such cases urgent rigid bronchoscopy is the better choice of treatment and sometime surgical removal is required.¹³

Early detection of central airway obstruction can be possible with monitoring signs and symptoms of respiratory failure in unintubated patient and monitoring ventilatory parameters in intubated patient. Successful management require immediate availability of flexible or rigid bronchoscope. In present case, first episode of tumour embolism was managed successfully as it occurred in immediate post operative period when patient was in ICU. But unfortunately, second time we did not get enough time outside the surgical and critical care setting. We presumed second episode of tumour embolism for the cause of death. The lesson we learnt from this case that there might be delayed tumour embolism so the critical monitoring should be extended in such cases.

We obtained the consent for publication from patient's relatives.

4. Conclusion

Acute episode of central airway obstruction can cause life threatening complications. Early detection and urgent interventions can avoid the catastrophe.

5. Source of Funding

None.

6. Conflict of Interest

None.

References

- Walsh CJ, Olivenstein R, Eric Forget & Anne V. Gonzalez. It's better to be lucky ... successful management of an acute endobronchial tumour embolism in the ICU: A case report and review of the literature. *Respirol Case Rep*. 2017;5(3):e00225.
- Compeau CG, Keshavjee S. Management of tracheal neoplasms. *Oncologist*. 1996;1(6):347–53.
- Ng YT, Chung P, Hsieh JR, Yu CC, Lau WM, Liu YH. Failure to provide adequate one-lung ventilation with a conventional endotracheal tube using a transbronchial approach: a case report. *Can J Anesth*. 2003;50:603–6.
- Regnard JF, Perrotin P, Giovannetti R. Resection for tumors with carinal involvement: technical. *Ann Thorac Surg*. 2005;80:1841–6.
- Kazumichi Y, Miyamoto Y, Ohsumi A, Imanishi N, Kojima F. Surgical results of carinal reconstruction: an alternative technique for tumors involving the tracheal carina. *Ann Thorac Surg*. 2007;84:216–20.
- Baz NE, Ganzouri AE, Gottschalk W, Jensik RJ. One lung high frequency positive-pressure ventilation for sleeve pneumonectomy: an alternative technique. *Anesth Analg*. 1981;60:683–6.
- Richa S, Satinder G, Sanjeev P, Usha D, Varinder S. Low tracheal tumor and airway management: An anesthetic challenge. *Saudi J Anaesth*. 2015;9(4):480–3.
- Jackson CL, Konzelmann FW. Bronchial carcinoma; bronchoscopic biopsy in series of 32 cases. *J Thorac Cardiovasc Surg*. 1934;4:165–87.
- Bolliger CT, Mathur PN, Beamis JF, Becker HD, Cavaliere S, Colt H, et al. ERS/ATS statement on interventional pulmonology. European Respiratory Society/American Thoracic Society. *Eur Respir J*. 2002;19(2):356–73.
- Bollen EC, Duin CJV, Noord JAV, Janssen JG, Theunissen PH. Tumor embolus in lung surgery. A case report and review of the literature. *Eur J Cardiothorac Surg*. 1973;7:104–6.
- Pathi V, Ramphal P, Sutherland F, Kirk A. Endobronchial tumour embolism: a preventable cause of death. *J Thorac Cardiovasc Surg*. 1996;112:844–5.
- Petrella F, Pietra A, Borri A, Galetta D, Gasparri R, Solli P, et al. Endobronchial Tumor Embolism. *J Bronchol Intervent Pulmonol*. 2013;20(4):366–8.
- Lee DK, Kim H, Lim SH, Choi YH, Kim HK. Bronchial obstruction by tumor embolus of contralateral lung during pneumonectomy: report of a case. *J Cardiothor Surg*. 2013;p. 8–26.

Author biography

Amit Bodkhe Consultant

Hemant Bhirud Intensivist

Sanjay Upadhye HOD

Meghana Nadkarni Consultant

Chitra Pitale Consultant

Avanti Purohit Fellow

Cite this article: Bodkhe A, Bhirud H, Upadhye S, Nadkarni M, Pitale C, Purohit A. Central airway obstruction in a patient of tracheobronchial carcinoma: A case report. *Indian J Clin Anaesth* 2020;7(2):363-366.