

Anatomical Single-Bundle Anterior Cruciate Ligament Reconstruction Using Medial Portal Technique.

Owais Ahmed Qureshi¹, Najamul Huda²

¹Assistant Professor, Department of Orthopaedic Surgery, Rama Medical College, Hospital & Research Centre, Hapur.

²Professor, Department of Orthopaedic Surgery, TMU, Moradabad.

Received: November 2016

Accepted: December 2016

Copyright: © the author(s), publisher. Annals of International medical and Dental Research (AIMDR) is an Official Publication of "Society for Health Care & Research Development". It is an open-access article distributed under the terms of the Creative Commons Attribution Non-Commercial License, which permits unrestricted non-commercial use, distribution, and reproduction in any medium, provided the original work is properly cited.

ABSTRACT

Background: The traditional transtibial approach can limit anatomical placement of the femoral tunnel in anterior cruciate ligament (ACL) reconstruction. Placement of an ACL graft within the anatomical femoral and tibial attachment sites is critical to the successful clinical outcome of ACL reconstruction. **Surgical Technique:** The medial portal technique was used for anatomic single bundle (SB) ACL reconstruction. **Methods:** Between November 2013 and October 2015, 30 ACL reconstructions were performed using the medial portal technique. All the patients were followed for a minimum of 06 months post-operatively. Clinical evaluation was done using the Lysholm score and International Knee Documentation Committee (IKDC) grade. **Results:** The mean Lysholm and the IKDC grade showed improvement at last follow up. None of the patients had a positive pivot shift test, anterior drawer test and Lachman test at final follow-up. **Conclusion:** The medial portal technique for anatomical SB ACL reconstruction is a simple technique showing good clinical results.

Keywords: Anterior cruciate ligament, Reconstruction, Anatomical, Single-bundle, Medial Portal Technique.

INTRODUCTION

Positioning the ACL femoral and tibial bone tunnels at the center of the native ACL femoral and tibial attachment is called as anatomical ACL graft placement and is considered critical to the success of ACL reconstruction. Non-anatomical ACL graft placement is the most common cause leading to recurrent instability following ACL reconstruction.^[1,2] Commonly ACL reconstruction has been performed using a transtibial technique in which the ACL femoral tunnel is drilled through a tibial tunnel positioned in the posterior half of the native ACL tibial attachment site.

Name & Address of Corresponding Author

Dr. Owais Ahmed Qureshi,
Assistant Professor,
Department of Orthopaedic Surgery,
Rama Medical College, Hospital & Research Centre,
Hapur.

Positioning the ACL tibial tunnel in the posterior half of the ACL tibial attachment site results in ACL femoral tunnel too high and deep in the intercondylar notch, outside of the native ACL

femoral attachment site [Figure 1]. An ACL graft in such tunnels will be vertically oriented in both the coronal and sagittal planes. A vertically oriented ACL graft may resist the anterior tibial translation, but may fail to control the pivot-shift phenomenon.^[3-6] This may lead the patient to experiencing continued symptoms of instability and giving-way episodes due to the pivot-shift phenomenon.

The medial portal technique offers a number of advantages over the transtibial technique.^[7]

1. Does not require any special guides or instrumentation.
2. The femoral tunnel can be drilled without the loss of joint distention due to fluid extravasation out of the tibial tunnel, giving better visualization.
3. Placement of the femoral tunnel within the native ACL femoral footprint.
4. A longer tibial tunnel can be drilled, which minimizes graft-tunnel length mismatch and allows longer bone-tendon-bone grafts to be used.
5. Insertion of the femoral interference fixation screw through the medial portal, which was used to drill the ACL femoral tunnel, avoids screw-tunnel divergence as seen in transtibial technique.

Surgical Technique

A standard anterolateral (AL) portal was placed for diagnostic arthroscopy. After confirming the diagnosis of ACL tear by arthroscopic examination of the knee joint, the ipsilateral hamstring tendons (both semitendinosus and gracilis tendons) were harvested using a closed tendon stripper through an oblique skin incision along the distal insertion of the tendons on the proximal tibia and prepared as a 4-strand double loop graft. While the graft was being prepared and sized by an assistant an anteromedial (AM) portal was established making sure that the instrument placed through the AM portal would be able to reach the posterior margin of lateral wall of the femoral notch without damaging the medial femoral condyle. Clearing of the notch was done to improve visualization of the native tibial and femoral footprints of ACL [Figure 1]. A radiofrequency ablator was used to clear the notch rather than a mechanical shaver so that bony landmarks could be preserved and care was taken to clear the lateral wall of the femoral notch right till the over the top position. Any associated meniscal and synovial pathology was addressed.

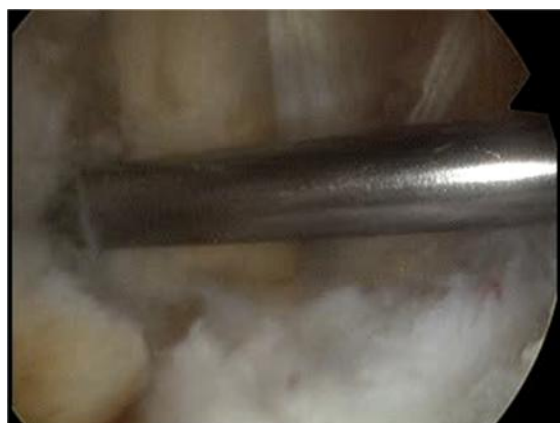

Figure 1: Femoral notch cleaned and femoral ACL footprint identified.



Figure 2: Drill site for femoral tunnel approached through an offset guide placed through AM portal.

Under direct arthroscopic visualization at 90° flexion, the center of the femoral footprint was located and marked with a microfracture awl at 10-

o'clock position (right knee)/2-o'clock position (left knee), corresponding to center of the femoral ACL footprint within the knee.^[8]



Figure 3: Cannulated drill over guide wire.



Figure 4: Femoral tunnel length measured.

Arthroscopic over the top offset guides, available with different offsets were routinely used. The offset guide aims to preserve a 2 mm posterior wall in the femoral tunnel. In a 10 mm diameter femoral tunnel (5 mm radius), an offset guide of 7 mm ($5+2 = 7$ mm) will be adequate to maintain 2 mm of the posterior wall. With the knee at 90° flexion, appropriate offset guide was introduced through the AM portal and after fixing it at the over the top position it was rotated so that it guides the pin into the lateral condyle at the level of the center of the femoral footprint previously marked [Figure 2]. Just the tip of the guide pin was drilled through the offset guide so that the entry point of the pin was marked. With the guide pin held in the same position, the knee was moved to 120° flexion and the guide pin is further drilled to exit out of the skin on the anterolateral aspect of the thigh. By using the intraarticular marking of center of femoral ACL footprint as guide for introducing the femoral guide pin, there was no case in which the pin is exited too posterior or too anterior with respect to the femoral shaft. A 5 mm cannulated drill bit was used to drill over the guide pin and exit out of the lateral femoral cortex [Figure 3]. The length of this

femoral tunnel was measured using a depth gauge [Figure 4]. A reamer of the same size as the femoral end graft diameter was used to create the blind-ended femoral tunnel according to the length of the graft to be kept inside the tunnel and at least 8mm of extra length of tunnel required to flip the endobutton [Figure 5,6]. A suture loop (#5 ethibond) was passed through the distal end of the guide pin and pulled out of the proximal exit point, so that one end of the suture exited from the anterolateral aspect of the thigh and the other from the AM portal [Figure 7]. Both ends of the suture were held with an artery forceps, out of the surgical field.



Figure 5,6: Femoral tunnel reamed through AM portal to desired length.



Figure 7: Suture loop passed through femoral tunnel.

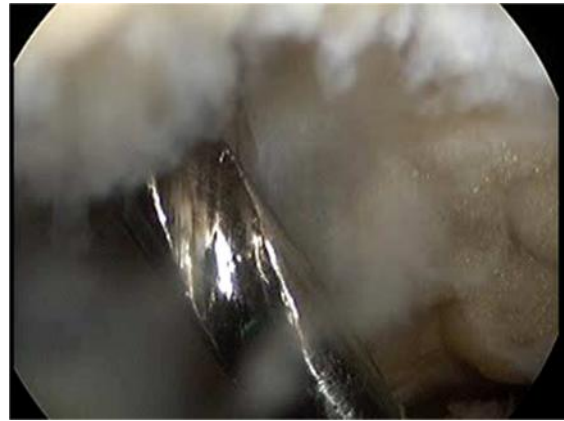

Figure 8: Tibial guide pin passed through tibial ACL footprint.

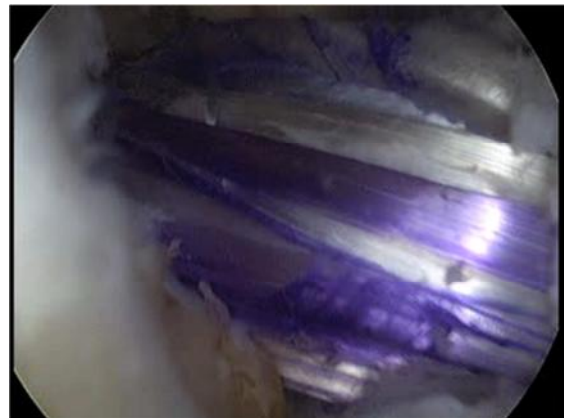

Figure 9: Graft pulled into femoral tunnel.

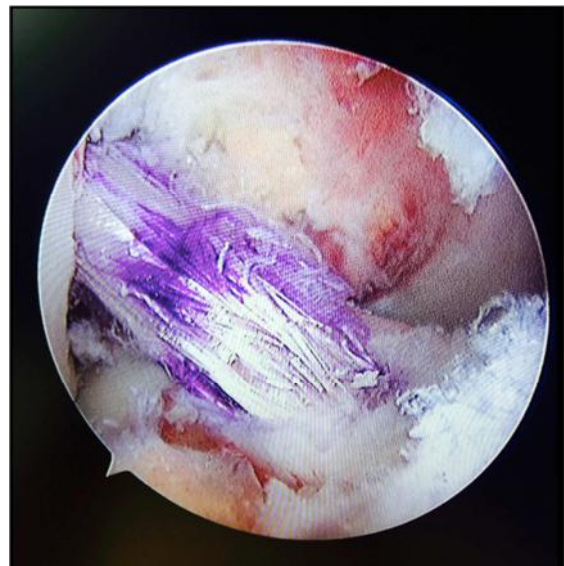


Figure 10: Position of graft after final tightening of tibial interference screws. Large angle of divergence seen between PCL and ACL graft.

For drilling the tibial tunnel, the knee was kept at 90° flexion and the tip pointing ACL guide was positioned just posterior to the anterior horn of the lateral meniscus on the antero lateral surface of the medial tibial spine, in the middle of the tibial ACL footprint. A guide pin was drilled into the proximal

tibia from a point located half way between the tibial tubercle and the posteromedial corner of the tibia and exiting into the joint at the previously identified site [Figure 8]. Fully extending the knee and ensuring that there was no impingement of the guide pin against the roof of the femoral notch further confirmed the position of the tibial guide pin. A cannulated reamer with the same diameter as the tibial end of the graft was used to drill the tibial tunnel.

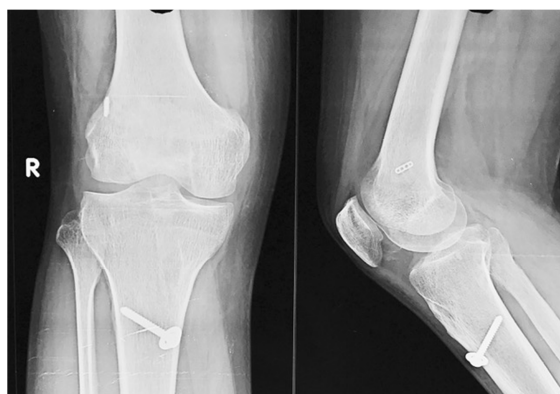

Figure 11: 12 week post op X ray shows no widening of tunnels.

An arthroscopic grasper was inserted through the tibial tunnel and the suture loop, which was previously positioned in the femoral tunnel, was pulled out of the tibial tunnel. The femoral end of the prepared quadrupled hamstring graft was looped around the endobutton loop, (Smith and Nephew, Andover, USA) which was pulled into the joint through the tibial tunnel and into the femoral tunnel under arthroscopic visualization [Figure 9]. Traction was maintained on the pulling suture of the endobutton till it was flipped against the lateral femoral cortex. Secure fixation of the endobutton was confirmed by pulling on the graft causing movement of the whole patient. The graft was cycled and then the tibial end of the graft was fixed with an interference screw (RCI, Smith and Nephew, Andover, USA) while the knee was held in 10°- 20° flexion and maximal tension was maintained on the graft [Figure 10].

MATERIALS AND METHODS

Between November 2013 and October 2015, 30 procedures were performed using the medial portal technique for anatomical SB ACL reconstruction using autologous quadrupled hamstring graft. The patients' average age was 36 years (range, 20 to 45 years). All patients were male and fall from a two-wheeler was the most common cause of injury. Post operatively a standard rehab protocol was followed for all patients. All the patients were followed for a minimum of 06 months postoperatively. The mean follow-up period was 14

months (range, 06 to 24 months) [Table 1]. Evaluation of clinical results was done using the Lysholm score and objective International Knee Documentation Committee (IKDC) grade [Table 2].

Table 1: Patient Demographics

Variable	Range
Number of patients	30
Age (years)	36 (20-40)
Gender	Males
Coexisting Injury	Medial Meniscal Tear-12 Lateral Meniscal Tear- 2
Follow-up (months)	14 (6-24)

Table 2: Clinical Results

Characteristics	Preoperative	Postoperative
Modified Lysholm Score	66.4±10.6	88.2±6.4
IKDC Grade		
Normal	0	23
Nearly Normal	0	07
Abnormal	17	0
Severely abnormal	13	0

RESULTS

On clinical assessment all the patients showed good or excellent clinical outcomes in the Lysholm score with a median score of 88.2 at final follow-up. The IKDC grade at final follow-up was normal in 23 patients and nearly normal in 07 patients [Table 2]. None of the patients had a positive pivot shift test, anterior drawer test and Lachman test at final follow-up. Radiographs done during follow up did not show tunnel widening or implant migration in any case [Figure 11].

DISCUSSION

ACL reconstruction is fast becoming a commonly performed orthopaedic procedure. In USA alone over 100,000 ACL reconstructions are performed per year in the United States.^[9] It has been proposed that abnormal knee kinematics is one of the primary causes of the development of osteoarthritis (OA) after ACL reconstruction.^[10,11] It is hoped that anatomical ACL reconstruction, which restores the normal knee kinematics in patients with functionally unstable ACL deficient knees will reduce the long-term incidence of OA. Clinical and biomechanical studies have conclusively demonstrated that a vertically placed graft may restore anterior tibial translation but shows a less effective resistance to rotatory load compared to a lower and more horizontally oriented graft.^[12] Recent biomechanical studies have suggested that a femoral tunnel placed centrally within the native ACL and posteriorly on the lateral wall of intercondylar notch by the trans-AM portal technique can restore both anterior and rotational

stability of the knee leading to superior clinical outcomes than the traditionally oriented femoral tunnels.^[5]

The key to anatomical ACL reconstruction is accurate identification of anatomy of the ACL origin.^[13-15] Although the lateral intercondylar ridge and lateral bifurcate ridge have been described, they can be difficult to visualize.^[16] The center of the ACL has been as being within 2 mm of an arthroscopic reference point located at the junction of a line drawn distally from the most proximal corner of the articular margin on the lateral wall of the notch and a perpendicular line drawn to the most posterior point of the condyle.^[17] Other techniques have also been described, which bring the femoral tunnel lower down on the wall of the lateral femoral condyle near the anatomic attachment of the ACL.^[18-21]

On the tibial side the anteromedial bundle is located at 30% and the posterolateral bundle 44% from anterior to posterior.^[22] Use of 3D CT has been used to validate the femoral and tibial tunnel positions post operatively.^[23-25]

The use of intra-operative fluoroscopy to locate the tunnel starting points has been described but it is time consuming and makes the rest of the surgery more difficult due to cumbersome radiation protection gowns.^[26] It also adds additional cost to the procedure.

Drilling through the AM portal has made the low placement of the femoral tunnel on the wall of the lateral femoral condyle easier.^[27] If done carefully one can avoid contact of the drill with the articular surface of the medial femoral condyle. The use of flexible drilling systems has improved the safety of this procedure.^[28] Some surgeons may use two anteromedial portals: a high portal close to the patella tendon providing visualization and a second more medial portal just above the meniscus for instrumentation. These independent drilling methods have been shown to produce tunnels with superior function compared with tunnels produced by conventional transtibial drilling methods.^[29-32]

There is still a lot of controversy regarding creating of anatomical tunnels using transtibial tunnel drilling.^[33] Recently a comparison of two tibial entry points to determine whether the anatomical femoral origin of the ACL could be reached using a transtibial technique showed that a more proximal and medial entry point 15.9 mm distal to the joint line and 9.8 mm medial to the tibial tubercle allowed the insertion site to be reached. These authors concluded that femoral tunnels could be positioned in an anatomic manner however the starting point offers little margin for error.^[34] Others have established that the use of a transtibial drilling technique resulted in a non-anatomic superior and posterior femoral tunnel.^[35]

On comparison of transtibial and anteromedial drilling techniques, the transtibial tunnels were

significantly more anterior and there was significantly more angulation towards the lateral condylar cortex as compared to anteromedial portal drilling. These authors concluded that AM portal drilling results in tunnels, which allow stabilization for both anterior tibial translation and rotational instability.^[36]

Another advantage that an anatomic approach to primary, revision and augmentation anterior cruciate ligament reconstruction offers is that it allows an intact bundle to be preserved so that only reconstruction of the deficient bundle may be performed.^[37]

A recently emerging concept is that of complete footprint restoration. It is based on the hypothesis that restoration of the biomechanical function of an ACL restored knee is a function of the reconstructed ACL insertion site area. There are natural variations in insertion site morphology with length measurement between 8– 21 mm. Small footprints up to 13 mm can be restored using anatomical single bundle reconstruction whereas larger double bundle grafts may be required for footprints of 16 mm or more.^[38]

The major limitation of this study includes the small number of patients and the lack of any direct comparison with traditional techniques. Studies with a larger number of patients need to be performed to establish the superiority of this technique over the traditional techniques.

REFERENCES

1. Kamath GV, Redfern JC, Greis PE, Burks RT. Revision anterior cruciate ligament reconstruction. *Am J Sports Med.* 2011; 39:199–217
2. Marchant B, Noyes F, Barber-Westin S, Fleckenstein C. Prevalence of nonanatomical graft placement in a series of failed anterior cruciate ligament reconstruction. *Am J Sports Med.* 2010; 38:1987– 1996
3. Kato Y, Ingham JM, Kramer S, Smolinski P, Saito P, Fu F. Effect of tunnel position for anatomic single-bundle ACL reconstruction on knee biomechanics in a porcine model. *Knee Surg Sports Traumatol Arthrosc.* 2010; 18:2–10
4. Driscoll MD, Isabell GP, Conditt MA, Ismaily BS, Jupiter DC, Noble PC, Lowe WR. Comparison of 2 femoral tunnel locations in anatomic single-bundle anterior cruciate ligament reconstruction: a biomechanical study. *Arthroscopy.* 2012; 28:1481–1489
5. Bedi A, Musahl V, Steuber V, Kendoff D, Choi D, Allen AA, Pearle AD, Altchek DW. Transtibial versus anteromedial portal reaming in anterior cruciate ligament reconstruction: an anatomic and biomechanical evaluation of surgical technique. *Arthroscopy.* 2011; 27:380–390
6. Steiner ME, Battaglia TC, Heming JF, Rand JD, Festa A, Baria M. Independent drilling outperforms conventional transtibial drilling in anterior cruciate ligament reconstruction. *Am J Sports Med.* 2009; 37:1912–1919
7. Brown Jr. C H, Spalding T, Robb C. Medial portal technique for single bundle anatomical anterior cruciate ligament reconstruction *International Orthopaedics (SICOT).* 2013; 37:253-269
8. Loh JC, Fukuda Y, Tsuda E. Knee stability and graft function following Anterior cruciate ligament reconstruction

- between 11 o'clock and 10 o'clock femoral tunnel placement: 2002 Richard O'Connor Award Paper. *Arthroscopy*. 2003; 19:297-304
9. Griffin LY, Albohm MJ, Arndt EA, et al. Understanding and preventing non-contact ACL injuries. A review of the Hunt Valley II meeting January 2005. *Am J Sports Med*. 2006; 34:1512-32.
 10. Oiestad BE, Holm I, Aune AK, et al. Knee function and prevalence of knee osteoarthritis after anterior cruciate reconstructions: a prospective study with 10-15 year follow up. *Am J Sports Med*. 2010; 38:2201-10.
 11. Lohmander LS, Englund PM, Dahl LL, Roos EM. The long-term consequences of anterior cruciate ligament and meniscus injuries: osteoarthritis. *Am J Sports Med*. 2007; 16:323-9.
 12. Lee MC, Seong SC, Lee S, Chang CB, Park YK, Jo H, Kim CH. Vertical femoral tunnel placement results in rotational knee laxity after anterior cruciate ligament reconstruction. *Arthroscopy*. 2007; 23:771-8
 13. Karlsson J. Anatomy is the key. *Knee Surg Sports Traumatol Arthrosc*. 2010; 18:1.
 14. Fu FH, Jordan SS. The lateral intercondylar ridge: a key to anatomic anterior cruciate ligament reconstruction. *J Bone Joint Surg Am*. 2007; 89:2103-4.
 15. Zantop T, Kuso S, Petersen W, Musahl V, Fu FH. Current techniques in anatomic anterior cruciate ligament reconstruction. *Arthroscopy*. 2007; 23:938-47.
 16. Ferretti M, Ekdahl M, Shen W, Fu FH. Osseous landmarks of the femoral attachment of the anterior cruciate ligament: an anatomic study. *Arthroscopy*. 2007; 23:1218-25.
 17. Kaseta MK, DeFrate LE, Charnock BL, Sullivan RT, Garrett Jr WE. Reconstruction techniques affect femoral tunnel placement in ACL reconstruction. *Clin Orth Relat Res*. 2008; 466:1467-74.
 18. Bird J, Carmont MR, Smith N, Brown C, Thompson P, Spalding T. Validation of a new technique to determine femoral mid-bundle tunnel position in Anterior Cruciate Ligament reconstruction using 3D Computer Tomography analysis. *Arthroscopy*. 2011
 19. Bernard M, Hertel P. Intraoperative and postoperative insertion control of anterior cruciate ligamentoplasty. A radiologic measuring method (quadrant method). *Unfallchirurg*. 1996; 99:332-40.
 20. Lee BI, Kwon SW, Kim JB, Choi HS, Min KD. Comparison of clinical results according to amount of preserved remnant in arthroscopic anterior cruciate ligament reconstruction using quadrupled hamstring graft. *Arthroscopy*. 2008; 24:560-8.
 21. Yasuda K, Kondo E, Ichiyama H, Tanabe Y, Tohyama H. Clinical evaluation of anatomic double bundle anterior cruciate ligament reconstruction procedure using hamstring tendon grafts: comparisons among 3 different procedures. *Arthroscopy*. 2006; 22:240-51
 22. Staubli HU, Rauschnig W. Tibial attachment area of the anterior cruciate ligament in the extended knee position anatomy and cryosections in vitro complemented by magnetic resonance arthrography in vivo. *Knee Surg Sports Traumatol Arthrosc*. 1994; 2:138-46.
 23. Steiner M. Anatomic single bundle ACL reconstruction. *Sports Med Arthrosc*. 2009; 17:247-51.
 24. Basdekis G, Christel P, Anne F. Validation of the position of the femoral tunnels in anatomic double bundle ACL reconstruction with 3D CT scan. *Knee Surg Sports Traumatol Arthrosc*. 2009; 17:1089-94.
 25. Forsythe B, Kopf S, Wong AK, et al. The location of femoral and tibial tunnels in anatomic double bundle anterior cruciate ligament reconstruction analyzed by three dimensional computed tomography models. *J Bone Joint Surg Am*. 2010; 92:1418-26.
 26. Kasten P, Szczodry M, Irrgang J, et al. What is the role of intra-operative fluoroscopic measurements to determine tibial tunnel placement in anatomical anterior cruciate ligament reconstruction. *Knee Surg Sports Traumatol Arthrosc*. 2010; 18:1169-75
 27. Harner CD, Honkamp NJ, Ranawat AS. Anteromedial portal technique for creating the anterior cruciate ligament femoral tunnel. *Arthroscopy*. 2008; 24:113-5.
 28. Bedi A, Altchek DW. The "footprint" anterior cruciate ligament technique: an anatomic approach to anterior cruciate ligament reconstruction. *Arthroscopy*. 2009; 25:1128-38.
 29. Lubowitz JH. Anteromedial technique for the anterior cruciate ligament femoral socket: pitfalls and solutions. *Arthroscopy*. 2009; 25:95-101.
 30. Silver AG, Kaar SG, Grisell MK, Reagan JM, Farrow LD. Comparison between rigid and flexible systems for drilling the femoral tunnel through an anteromedial portal in anterior cruciate ligament reconstruction. *Arthroscopy*. 2010; 26:790-5.
 31. Kopf S, Pombo MW, Shen W, Irrgang JJ, Fu FH. The ability of 3 different approaches to restore the anatomic AM bundle femoral insertion site during anatomic ACL reconstruction. *Arthroscopy*. 2011; 27:200-6.
 32. Steiner ME. Independent drilling of tibial and femoral tunnels in ACL reconstruction. *J Knee Surg*. 2009; 22:171-6.
 33. Heming JF, Rand J, Steiner ME. Anatomical limitations of transtibial drilling in ACL reconstruction. *Am J Sports Med*. 2007; 35:1708-15.
 34. Piasecki DP, Bach BR Jr, Espinoza Oras AA, Verma NN. Anterior cruciate ligament reconstruction: Can anatomic femoral placement be achieved with transtibial technique? *Am J Sports Med* 2011.
 35. Strauss EJ, Barker JU, McGill K et al. Can anatomic femoral tunnel placement be achieved using a transtibial technique for hamstring anterior cruciate ligament reconstruction. *Am J Sports Med* 2011.
 36. Dargel J, Schmidt-Wiethoff R, Fischer S, et al. Femoral bone tunnel placement using the transtibial tunnel or the anteromedial portal in ACL reconstruction: a radiographic evaluation. *Knee Surg Sports Traumatol Arthrosc*. 2009; 17:220-7.
 37. Van Eck CF, Lesniak BP, Schrieber VM, Fu FH. Anatomic single and double bundle anterior cruciate ligament reconstruction flowchart. *Arthroscopy*. 2010; 26:258-68.
 38. Siebold R. The concept of the complete footprint restoration with guidelines for single and double bundle ACL reconstruction. *Knee Surg Sports Traumatol Arthrosc* 2011.

How to cite this article: Qureshi OA, Huda N. Anatomical Single-Bundle Anterior Cruciate Ligament Reconstruction Using Medial Portal Technique. *Ann. Int. Med. Den. Res*. 2017; 3(1):OR38-OR43.

Source of Support: Nil, **Conflict of Interest:** None declared