



International Journal of Biological Innovations

Available online: <http://ijbi.org.in> | <http://www.gesa.org.in/journals.php>

DOI: <https://doi.org/10.46505/IJBI.2019.1102>



Research Article

E-ISSN: 2582-1032

Effect of Zinc on the Histopathology of Gill, Liver and Kidney of Fresh Water Catfish, *Clarias batrachus* (Linn.)

Navneet Kunwer Srivastava¹ and Sadguru Prakash^{2*}

¹Mewar University Gangrar, Chittorgarh (Rajasthan), India

²M.L.K. (P.G.) College, Balrampur (U.P.), India

*Corresponding author: sadguruprakash@gmail.com

Received: 10.01.2019

Reviewed: 25.01.2019

Accepted: 31.01.2019

Abstract: The aim of the present study was to assess the toxic effect of Zinc on the histology of gill, liver and kidney of *Clarias batrachus* was studied. The fish were exposed to sublethal concentration of 96h LC₅₀ of zinc sulphate (37.22 mg/L) i.e. 10, 20 and 30 of mg/L ZnSO₄ for 30 and 45 days. The fish exposed to zinc sulphate showed fusion of secondary gill lamellae, mucous secretion, and reduction in length, rupturing of secondary gill lamellae and vacuolization were observed in the gill, enlargement of hepatocytes, necrosis, ruptured hepatocytes, space formation and vacuolization were observed in liver, disintegration of tubules, swelling of glomerulus, tubular necrosis and vacuolization were observed in kidney of *Clarias batrachus*.

Keywords: *Clarias batrachus*, Health, Histopathology, Teleost, Zinc.

Introduction

Heavy metal in the aquatic environments has been as a potential threat to the aquatic organisms including fishes. Metals are known to inhibit the several biochemical and physiological mechanism vital for fish metabolism. Due to presence of omega-3 fatty acids such as linolenic acid, decosa hexaenoic acid and eicosa pentaenoic acid, fishes are considered as a good source of animal protein. Omega fatty acid is also good for heart and helps to control diabetics by improving insulin action. DHA is essential for growth and development of fetus and also promotes learning ability in children and improved memory in adults. The agricultural drainage, sewage and industrial effluents supply the water bodies containing sediments with huge quantities of pesticides, fertilizers, inorganic anions and heavy metals. The natural and anthropogenic sources continuously release heavy metals into aquatic ecosystem. These heavy metal are not only to injurious the fish stock but also have threatened the human health due to their long persistence, bioaccumulation, biomagnifications and by incorporating into the food chain. Histopathology is now recognized as an important tool to evaluate the effects of contaminants in vital

processes such as growth and reproduction, detecting early effects in cells, tissues and organs (Adams, 2002). Histopathological changes have been widely used as biomarkers in the evaluation of the health of fish exposed to environmental pollutants because it allows examining specific target organs, including gills, kidney and liver, that are responsible for vital functions, such as respiration, excretion and the accumulation and biotransformation of xenobiotics in the fish (Gernhofer *et al.*, 2001). The present work was aimed to evaluate the long term exposure effects of sub lethal concentration of heavy metal zinc on the histology of gill, liver and kidney of *Clarias batrachus*.

Materials and Methods

Clarias batrachus (50-55g weight and 16-21cm length) irrespective of sex were collected from local fish farm of Balrampur and acclimatized to laboratory conditions. They were given the treatment of 0.1% KMnO₄ solution and then kept in plastic pools for acclimatization for a period of two weeks to the laboratory conditions. They were fed on boiled egg yolk and commercial fish food. Toxicant stock solution was prepared by dissolving zinc sulphate (43.97g) equivalent

to 1g of zinc in 1000ml distilled water at concentration of 1000mg/L. The final concentration was recalculated according to the amount of heavy metal ion.

The acclimatized fish were divided into four groups. On the basis of 96hr LC₅₀ of zinc sulphate (37.22 mg/L) for *Clarias batrachus* (Srivastava and Prakash, 2018), three sublethal concentrations groups *i.e.* 10, 20 and 30 mg/L of zinc sulphate were selected for exposed to the 45 days. The fourth, unexposed, group served as the control. After 30 and 45 days of exposure, the fish were scarified and liver, kidney and gill tissues of each group were collected carefully for histopathological examination. These tissues were then fixed in aqueous Bouin's fixative for 48 h with a change after 24 hours. Fixed tissues were washed with 50% ethanol and dehydrated further through 70%, 90% and absolute ethanol and cleared in xylene. The tissues were then embedded in paraffin wax (580 C) and sectioned at 6 microns thickness by rotary microtome. The sections gill, liver and kidney of *Clarias batrachus* were stained with eosin-haematoxylin and mounted with DPX (Gurr *et al.*, 1959). The stained slides were observed under compound microscope for examine histopathological changes and were photomicrographed.

Results and Discussion

Gill Histopathology

Gills are the most important organ for respiratory and osmoregulation in fishes. The gills are among the most delicate structures and owing to their external location it is first organ to which, toxicant comes into direct contact with surrounding water and are liable to more damage by any irritant materials, whether dissolved or suspended, in the water. Hence, it is more vulnerable to damage than any other tissue. The fish gill is very sensitive to physical and chemical alteration of the aquatic medium (Muthulingam *et al.*, 2015) Thus the any histopathological changes of the gills might impair the respiratory function of the gills by reducing respiratory surface area resulted in hypoxia, respiratory failure problems and this badly affects the physiology and may lead to death of fish. The untreated gills showed an arrangement of filaments (primary gill lamellae) in double rows on either side of the interbranchial septum and the secondary lamellae arise from these filaments. Primary gill lamellae comprised of a central core of cartilaginous rod, lining epithelial cells and blood vessels whereas secondary lamellae consisted of a layer of flattened epithelial cells attached to the basement membrane, contractile pillar cell system and blood spaces (Plate I; Fig.1).The gills of zinc exposed fishes showed excessive secretion of mucous in the inter-lamellar spaces, degenerative changes in epithelial cells of secondary gill filaments, moderate necrotic changes in inter lamellar epithelial cells and twisting and clubbing of secondary gill lamella tips. As the concentration of zinc sulphate and duration of exposure increased, the fusion of secondary gill lamellae, reduction in length, swelling and bulging of epithelial cells of secondary lamellae and cytoplasmic vacuolization, necrosis in the tip of secondary gill lamellae and degeneration in gill rays were observed

(Plate I; Fig.2-7). Some studies revealed that interstitial edema is one of the more frequent lesions observed in the gill epithelium of fish exposed to heavy metals (Mallatt, 1985). Edema with lifting of lamellar epithelium could be served as a mechanism of defense (Arellano *et al.*, 1999). The rupturing of secondary gill lamellae, excessive secretion of mucous, fusion of secondary gill lamellae, reduction in length, central core broken and vacuolization are some of the important histopathological abnormalities observed in the gill of *Channa punctatus* exposed to sub-lethal concentration of nickel chloride (Pandey *et al.*, 2008). Thus gill morphology is therefore a good indicator of the water quality and the general health condition of cultured fish.

Liver Histopathology

Liver is responsible for digestion, filtration and storage of food energy in the form of glycogen. It is the vital organ for detoxification of unwanted and toxic substances. Fish liver is susceptible to chemical damaged due to slow blood flow and lower rate of bile flow. As the liver has multiple metabolic functions, such damage can have serious effects on the metabolism. The normal liver of fish, *Clarias batrachus* is made up of polygonal hepatocytes (HC) with large spherical central nucleus and number of blood capillaries called sinusoids (SI). Kuffer cells (KC) were found to rest on luminal surface of sinusoids endothelium (Plate II; Fig.1). The fish exposed to the sublethal concentrations of zinc sulphate showed the vacuolation, loose arrangement of hepatocytes, blood capillaries become dilated *i.e.* dilated sinusoid and histolysis. As the concentration of zinc sulphate and duration of exposure increased, the hepatocytes becoming highly vacuolated, hypertrophy in hepatocytes and finally plasma membrane of cells disintegrate, congestion in blood capillaries, nuclei becomes eccentric and nuclei of such hepatocytes get clumped with each other, a phenomenon called nuclear pyknosis (PN) (Plate II; Fig.2-7). Athikesavan *et al.*, (2006) also observed degeneration of blood vessels hypertrophy, vacuolization necrosis and pyknotic nuclei of nickel exposed fish, *Hypophthalmichthys molitrix*. Loganathan *et al.*, (2006) and Radhakrishnan and Hemalatha (2010) observed cytoplasmic vacuolization of hepatocytes, congestion of blood vessel, leucocytic infiltration and necrosis in zinc exposed *Labeo rohita* and cadmium treated *Channa striatus*, respectively. Chavan and Muley (2014) observed significant increase in Kuffer cells in liver of *Cirrhinus mrigala* exposed to mercuric chloride and lead acetate. Thilagamani *et al.*, (1990) have suggested that the severe destruction of hepatocytes and formation of intercellular spaces could possibly due to sudden withdrawal and utilization of stored glycogen from the liver cells to meet the energy demands during toxicant stress in fish. The results of the present observation in *Clarias batrachus* exposed to zinc were in agreement with those of the earlier workers especially in the vacuolization, pyknotic nuclei and necrosis in hepatocytes. Intracellular vacuolization, necrosis and pyknotic nuclei were also apparent in the present study in zinc exposed *Clarias batrachus*. Thus degeneration, vacuolization and necrosis of hepatocytes; congestion of hepatic blood vessels and significant increase in Kuffer cells

in liver of zinc exposed *Clarias batrachus* were mainly due to cumulative effect of the metals and increase in their concentration in liver.

Kidney Histopathology

In fresh water teleost fish, kidneys excrete a large amount of nitrogenous wastes and help in maintaining water salt balance. It is the main route of excretion of toxic substances from body and major target organ for this toxicant. Thus kidney plays a vital role in homeostasis. The kidney of normal fish, *Clarias batrachus* is made up of tufts of capillaries forming glomerulus (G) surrounded by Bowman's capsule

(BC). Besides proximal and distal convoluted tubules (PCT & DCT) and collecting ducts are noticed (Plate III; Fig. 1). The fish exposed to the sublethal concentrations of zinc sulphate have shown the marked damage. The renal tubular cells were vacuolated, necrosis, vacuolization of cytoplasm are evident. The Bowman's capsule has a thick lining with shrunk glomerulus (SG), degenerated glomerulus, increase in the capsular space (ICS), with swelling and sloughing of the cells of the epithelium of capsule. The lumen of renal tubules shrunk (SL) considerably, disintegrated tubules (DT) and the degeneration in tubular epithelium i.e. necrosis in renal tubules (TN). Large vacuoles (VC) appear in

Plate 1 : Effect of ZnSO₄ on Gill of *Clarias batrachus* as seen in the section (400X).

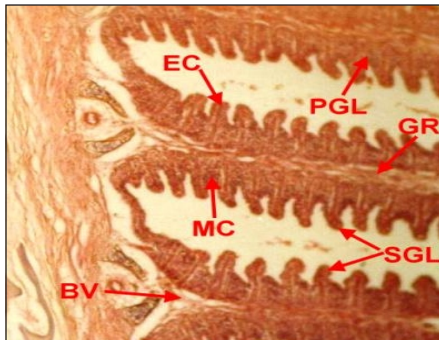


Fig. 1 : Control / Normal

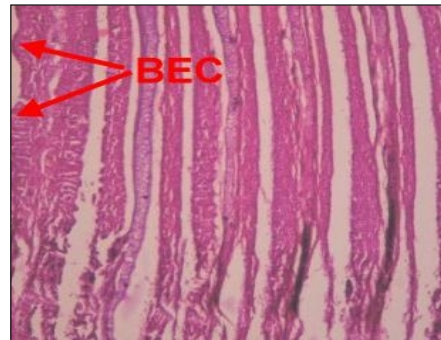

Fig. 2 : After 30 days exposure at 10mg/L ZnSO₄

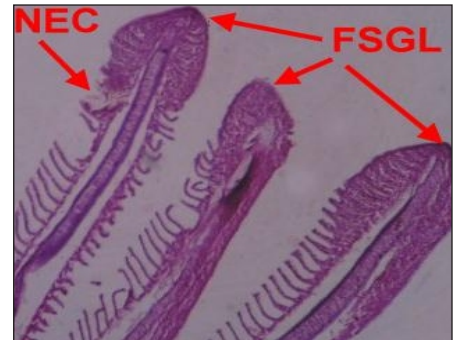


Fig. 3 : After 45 days exposure at 10mg/L ZnSO₄

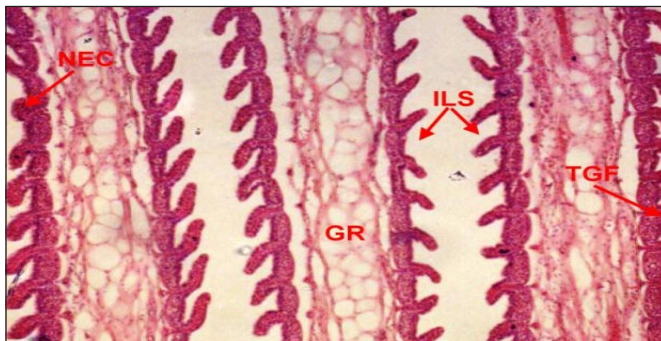


Fig. 4 : After 30 days exposure at 20mg/L ZnSO₄

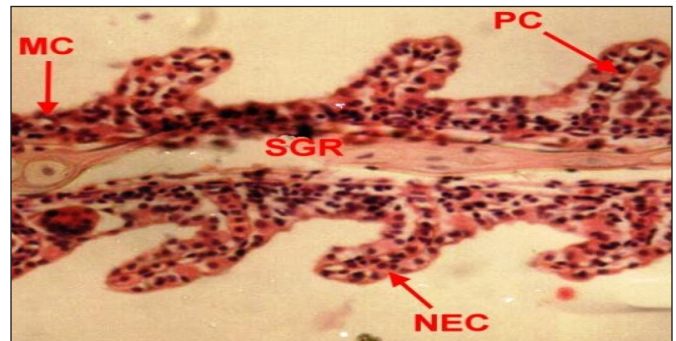


Fig. 5 : After 45 days exposure at 20mg/L ZnSO₄

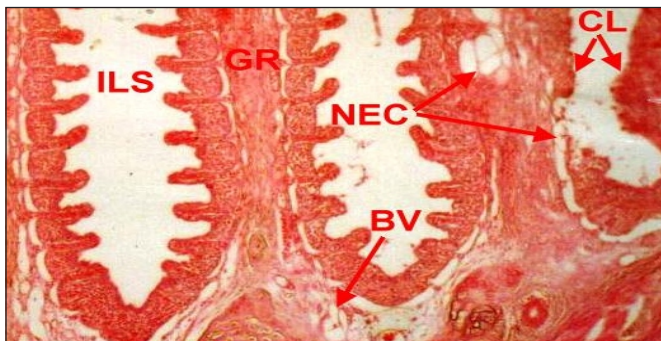


Fig. 6 : After 30 days exposure at 30mg/L ZnSO₄

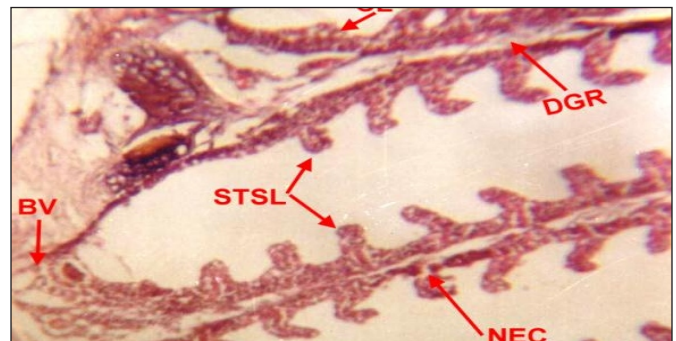

Fig. 7 : After 45 days exposure at 30mg/L ZnSO₄

Abbreviation: EC : Epithelial Cell, BEC : Bulbing of EC, NEC : Necrotic EC, PC : Pillar Cell, PGL : Primary Gill Lamellae, SGL: Secondary GL, STSL : Swollen tip of SL, FSGL : Fused SGL, CL : Clubbed Lamella, ILS : Inter-lamellar Space, NTSL : Necrotic in tip of SL, GR : Gill Ray, DGR : Degenerated GR.

Plate 2 : Effect of ZnSO₄ on Liver of *Clarias batrachus* as seen in the section (400X).

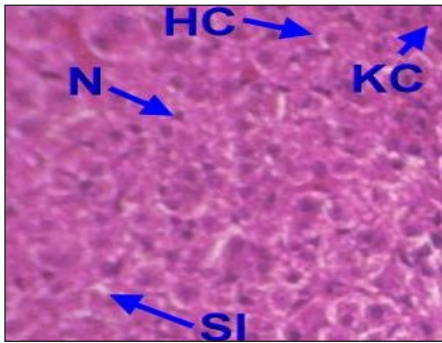


Fig. 1 : Control / Normal

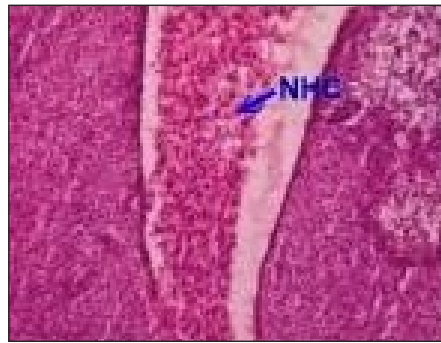


Fig. 2 : After 30 days exposure at 10mg/L ZnSO₄

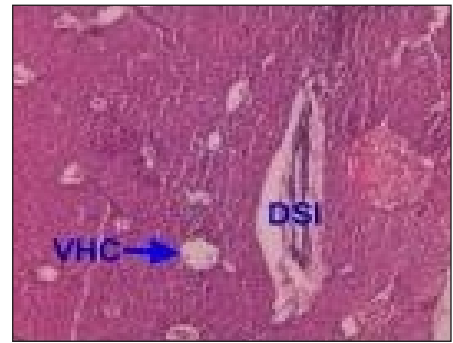

Fig. 3 : After 45 days exposure at 10mg/L ZnSO₄

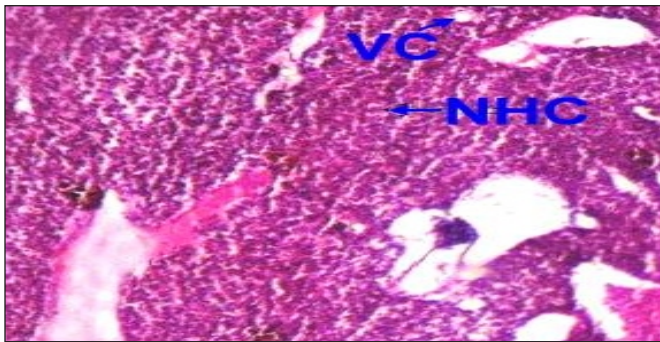


Fig. 4 : After 30 days exposure at 20mg/L ZnSO₄

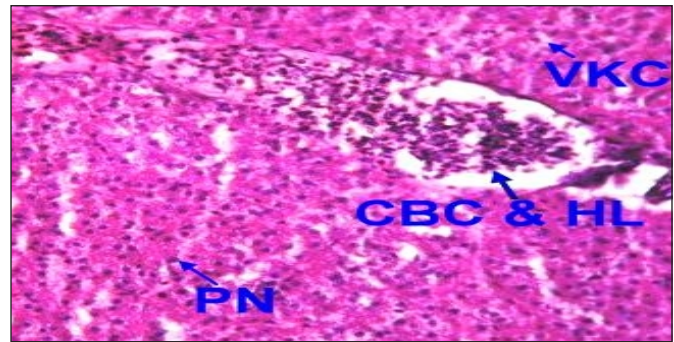


Fig. 5 : After 45 days exposure at 20mg/L ZnSO₄

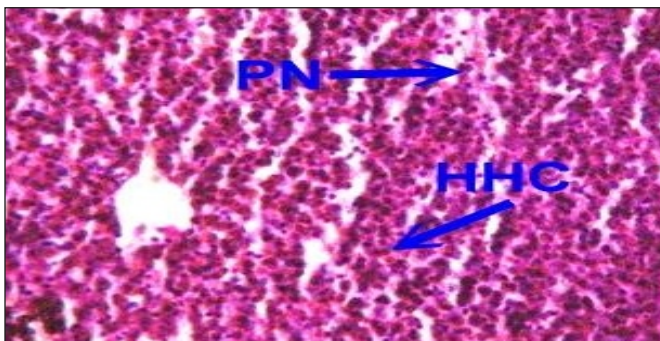


Fig. 6 : After 30 days exposure at 30mg/L ZnSO₄

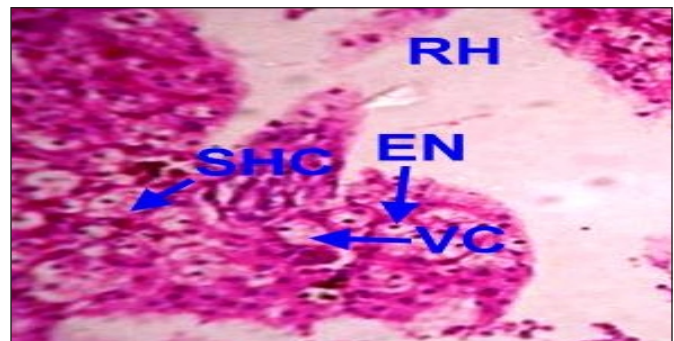


Fig. 7 : After 45 days exposure at 30mg/L ZnSO₄

Abbreviation: HC : Hepatocytes, HHC : Hipertrophy HC, SHC : Separated HC, NHC : Necrotic HC, RH : Ruptured HC, VC : Vacuolated Cell, VHC : Vacuolated HC, N : Nucleus, PN : Pyknotic N, EN : Eccentric N, DSI : Dilated Sinusoid, CBC : Congested Blood Capillary, HL : Haemolysis,

the cells lining the lumen and the nuclei of these cells have been pushed towards the center of the lumen. As the concentration of zinc sulphate and duration of exposure increased, the normal histology of the lumen is considerably disturbed with the tubular lumen is completely shrunken (Plate III; Fig.2-7). Similar histopathological changes have been observed by various workers in the kidney of heavy metal exposed fish. Muthulingam *et al.*, (2015) also observed the vacuolated renal tubular cells, necrosis, swelling of glomerulus, tubular necrosis, vacuolization of the cytoplasm and degeneration of tubular epithelium in nickel exposed fish, *Oreochromis mossambicus*. Sharma and Sharma (1994)

also observed the desquamation in epithelial cells of renal tubules in kidney, vacuolation, irregular orientation of nuclei and shrinkage of glomerular tuft and capsules. Jagadeesan (1994) has observed vacuolization, disintegration of kidney tubules and necrosis in mercuric chloride exposed *Labeo rohita*. Disintegration, vacuolization, necrosis of kidney tubules have also been noticed in *Mystus vittatus* treated with copper (Rajamanickam,1992). Thus in the present investigation shrinking in glomerulus and lumen tubules with swelling of epithelial cells of capsule and tubules, irregular orientation of nuclei and necrosis in the kidney of zinc exposed *Clarias batrachus* were mainly due to accumulation

Plate 3 : Effect of ZnSO₄ on Kidney of *Clarias batrachus* as seen in the section (400X).

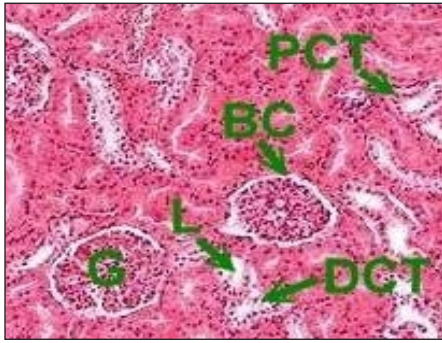

Fig. 1 : Control / Normal

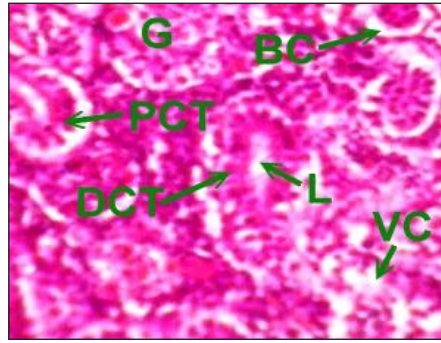


Fig. 2 : After 30 days exposure at 10mg/L ZnSO₄

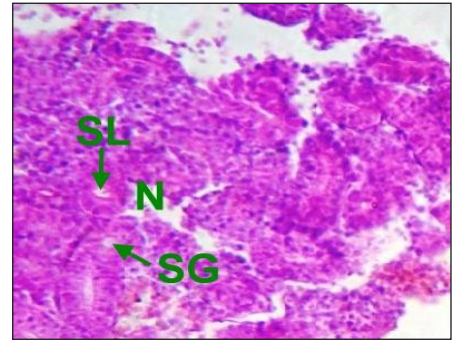


Fig. 3 : After 45 days exposure at 10mg/L ZnSO₄

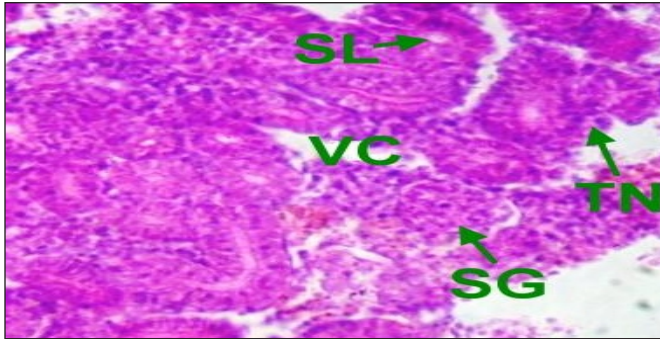


Fig. 4 : After 30 days exposure at 20mg/L ZnSO₄

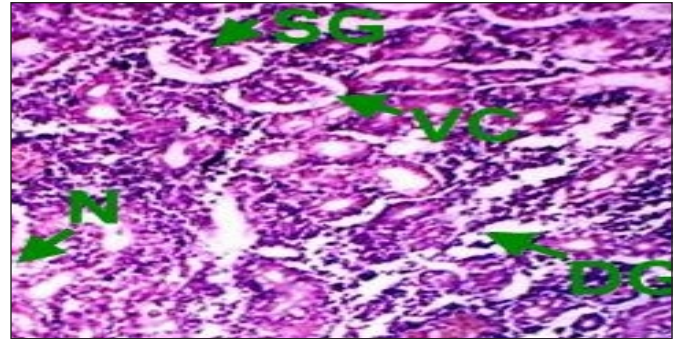


Fig. 5 : After 45 days exposure at 20mg/L ZnSO₄

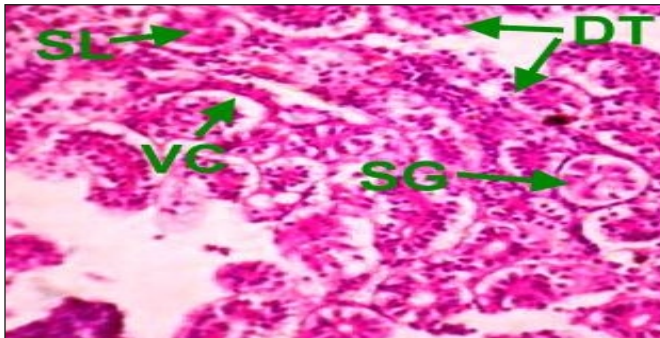


Fig. 6 : After 30 days exposure at 30mg/L ZnSO₄

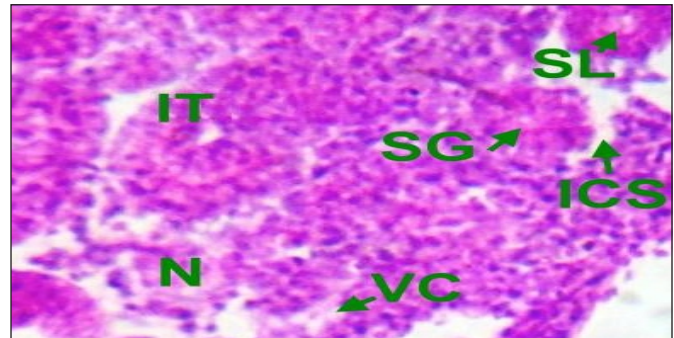


Fig. 7 : After 45 days exposure at 30mg/L ZnSO₄

Abbreviation: BC : Bowman's Capsule, G : Glomerulus, SG : Shrunken G, DG: Degenerated G, PCT : Proximal Convoluted Tubules, DCT : Distal CT, L : Lumen of Tubules, SL : Shrunken Lumen, DT : Disintegrated Tubules, TN : Necrosis in Tubules, IT : Inflated tubules, ICS : Increased Capsular Space, VC : Vacuolization, N : Necrosis.

and slow elimination processes of metal ions in the kidney may lead to renal lesions. The foregoing account clearly suggests that the toxic impact of zinc sulphate influences considerable changes in the histological organization of the gills, liver and kidney of *Clarias batrachus* leading to its functional disruption. In general, zinc sulphate creates manifold disturbances in the target tissues. Fishes are therefore particularly sensitive to environmental contamination of the water and pollutants like heavy metal may cause significant impairments of certain physiological and biochemical processes which can result in serious tissue damage.

Acknowledgement

Authors are grateful to Principal M.L.K. (P.G) College, Balrampur (U.P.) for providing necessary laboratory facilities.

REFERENCES

1. Adams S. M. (2002). Biological indicators of aquatic ecosystem stress. American Fisheries Society. 644p.
2. Arellano J. M., Storch V. and Sarasqete C. (1999). Histological changes and copper accumulation in liver and gills of the Senegales sole, *Solea senegalensis*. *Ecotoxicol. Environ. Saf.* 44(1):62-72.

3. **Athikesavan S., Vincent S., Ambrose T. and Velmurugan B.** (2006). Nickel induced histopathological changes in the different tissues of freshwater fish, *Hypophthalmichthys molitrix* (Valenciennes). *J. Environ. Biol.* 27(2 Suppl.):391-395.
4. **Chavan V.R. and Muley D.V.** (2014). Effect of heavy metals on liver and gill of fish *Cirrhinus mrigala*. *Int. J. Curr. Microbiol. App. Sci.* 3(5):277-288.
5. **Gernhofer M., Pawet M., Schraman M., Muller E. and Triebkorn R.** (2001). Ultrastructural biomarkers as tools to characterize the health status of fish in contaminated streams. *Journal of Aquatic Ecosystem Stress and Recovery.* 8:241-260.
6. **Gurr E.** (1958). Methods of analytical histology and histochemistry. Leonard Hill Book Ltd. London.
7. **Hemalatha S. and Banerjee T.K.** (1997). Histopathological analysis of sublethal toxicity of zinc chloride to the respiratory organs of the air breathing catfish *Heteropneustes fossilis* (Bloch). *Biol. Res.* 30(1):11-21.
8. **Jagadeesan G.** (1994). Studies on the toxic effects of mercuric chloride and the influence of Antidote Dimercaprol on selected tissues in *Labeo rohita* (Hamilton) fingerlings. Ph.D Thesis, Annamalai University, India.
9. **Kaoud H.A. and El-Dahshan A.R.** (2010). Bioaccumulation and histopathological alterations of the heavy metals in *Oreochromis niloticus* fish. *Nature Sci.* 8(4): 147-154.
10. **Loganathan K., Velmurugan B., Howrelia J. H., Selvanayagam M. and Patnaik B.B.** (2006). Zinc induced histological changes in brain and liver of *Labeo rohita* (Ham). *J. Cell. Tissue Res.* 10(3): 2365-2370.
11. **Mallatt J.** (1985). Fish gill structural changes induced by toxicants and other irritants: A statistical review. *Can. J. Fish. Aquat. Sci.* 42(4):630-648.
12. **Muthulingam M., Revath S.K., Ross P.R., Ravichandran S. and Thenmozhi P.** (2015). Effect of heavy metal, nickel chloride on histopathological biomarkers in gill, liver and kidney of fresh water fish, *Oreochromis mossambicus* (Peters). *Life Sci. Arch.* 1(3):166-174.
13. **Pandey S., Parvez S., Ansari R.A., Ali M., Kaur M., Hayat F., Ahmad F. and Raisuddin S.** (2008). Effects of exposure to multiple trace metals on biochemical, histological and ultrastructural features of gills of a freshwater fish, *Channa punctata* Bloch. *Chem Biol Interact.* 174(3):183-192.
14. **Radhakrishnan M.V. and Hemalatha S.** (2010). Sublethal toxicity effects of cadmium chloride to liver of freshwater fish *Channa striatus* (Bloch). *Am-Emuras. J. Toxicol. Sci.* 2(1): 54-56.
15. **Rajamanickam C.** (1992). Effect of heavy metal copper on the biochemical contents, bioaccumulation and histology of the selected organs in the fresh water fish, *Mystus vittatus* (Bloch.). Ph.D. Thesis. Annamalai University.
16. **Sharma A. and Sharma M.** (1994). Toxic effect of zinc smelter effluent to some developmental stages of fresh water fish, *Cyprinus carpio* (L.). *J. Environ. Bio.* 15(3):221-229.
17. **Srivastava N.K. and Prakash S.** (2018). Morphological, behavioural and haematological alterations in catfish, *Clarias batrachus* (Linn.) after acute Zinc toxicity. *International journal on Biological Sciences.* 9(1):78-84.
18. **Thilagamani K.B., Karuppaiah D. and Ramaswamy M.** (1990). Histopathological changes induced by a carbamate fungicide, Cuman L.in liver and brain of a teleost fish, *Sarotherodon mossambicus* (Peters). *The Indian Zoologists.* 14(1&2):135-139.
19. **Van Dyk J., Pieterse G. and Van Vuren J.** (2007). Histological changes in the liver of *Oreochromis mossambicus* (Cichlidae) after exposure to cadmium and zinc. *Ecotoxicol. Environ. Saf.* 66(3): 432-440.