



International Journal of Allied Medical Sciences and Clinical Research (IJAMSCR)

ISSN:2347-6567

IJAMSCR /Volume 4 / Issue 3 / July-Sep - 2016
www.ijamscr.com

Case Report

Medical research

Homicide represented as sudden natural death: A case report

Vinod Kumar*, **Jai Prakash Soni ****, **Vijaypal Khanagwal*****, **Vincent Merry****, **Dinesh Chhillar****

**Demonstrator, Department of Forensic Medicine, Pt.BDS PGIMS Rohtak, Haryana, India.*

*** Ex. Resident, Department of Forensic Medicine, Pt.BDS PGIMS Rohtak, Haryana, India.*

****Professor, Department of Forensic Medicine, Pt.BDS PGIMS Rohtak, Haryana, India.*

Corresponding Author: Jai Prakash Soni

Email: dr.jaiprakashsoni@gmail.com

ABSTRACT

In many instances, unnatural deaths are often presumed by family members/relatives to be due to natural causes like heart attack and stroke and vice-versa in also true sometimes. This is especially common amongst the rural folk where concealed/occult fatal injuries may not be appreciable to the naked eyes or when the dead body is found in circumstances not seen by any eye-witness or where no foul play is suspected. Often, sudden death is deliberately made up by family members to be on account of heart attack in order to conceal the crime committed by someone from amongst the family members. We encountered such a case wherein a 35 year old male individual who was working in the fields of a village was found dead early in the morning on the fateful day by family members. The family members were taking the dead body for performing final rites but someone from the village informed the Police that the death was due to some foul act, as injury was appreciable over the neck. The Police prepared the inquest Report and forwarded the body for autopsy at General Hospital, though the relatives were reluctant to have autopsy on the body claiming it to be a case of sudden natural death. The Medical Officers at General Hospital noticed some injuries over the body and explained to the relatives that it was not a case of sudden natural death. However, the relatives were not agreeing upon the impression of the Medical Officers regarding the cause of death and they were adamant to label it a case of sudden natural death. Ultimately, the Medical Officers had to refer the body for examination by experts of Forensic Medicine at our Institute. The autopsy done at our Institute revealed the truth. The details of the injuries and other important findings noticed in this case will be discussed in this paper.

Keywords: Heart attack, Ligature mark, Crescentic abrasions, Fractures of hyoid bone, Fracture of thyroid cartilage, Strangulation.

INTRODUCTION

It is very common in our country especially amongst the rural folk that to fabricate a false charge against an enemy, a relation is killed and then the opposite party is accused of murder. Even

when there is a natural death in the family, the relatives might make a false report to implicate their enemies and may attribute the death to some previous quarrel or fight that had taken place between the two parties. The opposite of the former

is rather not so common that a relation is first killed by the family and later such murder is represented as natural death. Some such cases of the so-called honour killing where a young boy or girl (having affairs thought to be disgraceful by the family) is killed and such murder is concealed by the family. We came across a case wherein a typical murder of a 35 years old male individual was represented by the family as natural death following heart attack in order to conceal the crime committed by the family. However, autopsy revealed the truth and the family could not conceal the truth of murder in this case.

CASE REPORT

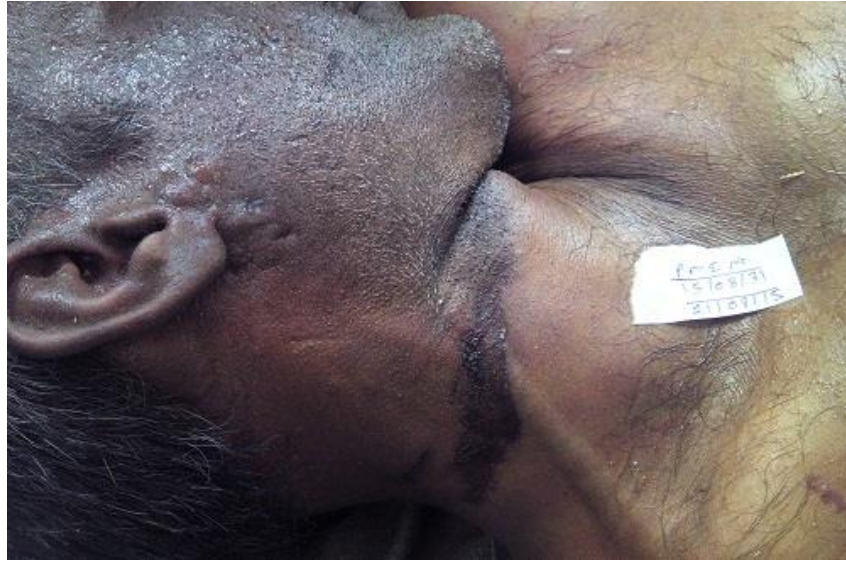It was a case of a 35 year old male individual who was working in the field a day before and the next day in the wee hours, he was found dead by family members. The family members claimed it to be a natural death due to sudden heart attack or bite by some wild animal or snake etc. and made the preparations for final rites (cremation). Incidentally, someone from the village informed the Police that the death in this case was not natural but it should be due to some foul play and that the family of the deceased was hiding the truth as was evident from the approach of the family in disposing off of the body. Ultimately, the Police prepared the inquest Report and forwarded the body for autopsy at General Hospital, though the relatives were reluctant to have autopsy on the body claiming it to be a case of sudden natural death. The Medical Officers at General Hospital noticed some injuries/ligature mark over the neck of deceased and explained to the relatives that it was not a case of sudden natural death but it was a case of murder. However, the family members did not agree with the impression of the Medical Officers regarding the cause of death rather they were adamant to label it to be a case of sudden

natural death and that did not want any autopsy in this case. Finally, the Medical Officers had to refer the body for examination by experts of Forensic Medicine at our Institute. The autopsy done at our Institute revealed the truth.

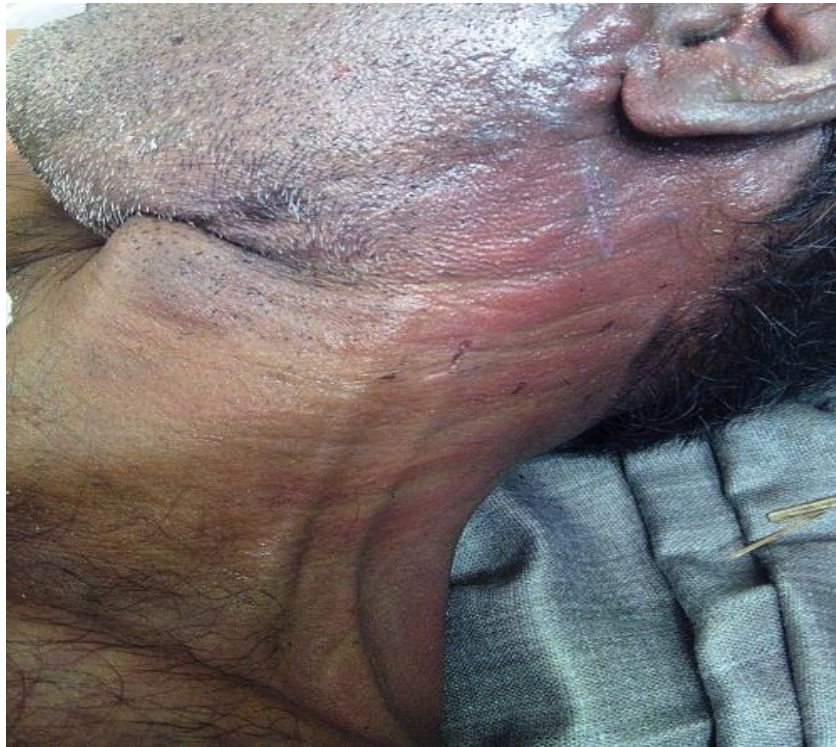AUTOPSY FINDINGS

Ligature mark-A reddish ligature mark over the front of neck at the level of thyroid cartilage, situated 5.5 cm below the centre of chin in midline, extending on both sides of neck in the transverse plane so as to completely encircle the neck in the same plane so as to lie 4 cm below the right angle of mandible, 4.5 cm below the left angle of mandible whereas over the nape of neck, it was 6.5 cm below the level of external occipital protuberance [Fig. 1]. On left side of neck, it was relatively faint. The width of the ligature mark varied between 1.5 cm to 2.5 cm. On dissection, the underlying neck structures including the subcutaneous tissues, muscles, laryngo-tracheal and cricoids and thyroid cartilages were deeply ecchymosed [Fig. 3] along with fracture of the greater cornu of hyoid bone and thyroid cartilage on the right side were seen. [1,2,3]

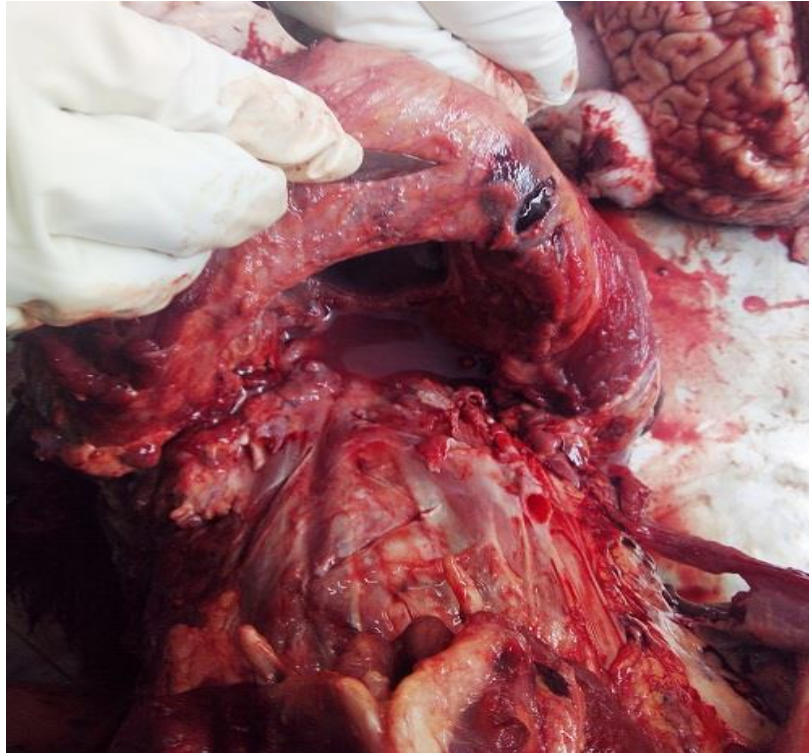
In addition to the above ligature mark over the neck, multiple crescentic abrasions [Fig. 2] were also noticed over the lateral aspect of left side of neck. [4] Multiple injuries in the form of abrasions over the face, anterior abdominal wall and right arm and contusions over left shoulder, left forearm and both the legs were also noticed. Generalized visceral congestion was also evident in this case. Cause of death. The cause of death was opined to be due to "strangulation by ligature". In strangulation, the cause of death is cerebral hypoxia secondary to compression and thereby an occlusion of the vessels supplying blood to the brain. [5]



Legend of figure-1:- Ligature mark.



Legend of figure-2:- Multiple crescentic abrasions.



Legend of figure-3:- Underlying neck tissue was ecchymosed.

DISCUSSION

The cause of death could be established after autopsy which was strangulation by ligature. Besides this, multiple ante-mortem injuries including crescentic nail marks were also noticed over the body which was indicative of the signs of struggle which took place between the victim and assailant. But the strange thing was that family members had no issue with the cause of death rather they claimed it to be a natural death due to heart attack. However, the thorough and meticulous autopsy proved them to be wrong.

MOTIVE OF MURDER??

The deceased had an unpleasant history of bad alcohol-drinking habit. He started drinking at all times in the day, evening and even at night. Even after being married for the last 7 years and having responsibility of bringing up the family including 3 children, he could not give up this vice and turn over a new leaf to become a responsible father and husband despite persistent advice and suggestions of everyone including the elder ones in the family. On the contrary, he resorted to abusing his wife and children whenever under the influence of alcohol.

In order to meet his daily supply of alcohol, he started selling off whatever meager amount of land was in his possession. This infuriated his wife who developed a firm conviction in her mind that her alcoholic husband has made her life hell and miserable. On eventful night he abused and beaten her wife, but at this time, she ultimately decided to get rid of her alcoholic husband in connivance with her nephew and ultimately strangled him to death. His bad habit had therefore cost him his life.

BODY DISPOSED IN THE FIELD – WHY??

In Haryana state Government runs a scheme in which they give compensation of 5 lacs for the farmer who was died in the field. As the family members thought that they had got rid of an abusive alcoholic and burdensome member of the family anticipated some relief for other members of the family and they must have felt justified in concealing the crime so committed. And for the above reason they kept the body in the field so that they may claim for compensation for natural death during in the fields from the Government run scheme.

CONCLUSION

A thorough and meticulous autopsy always helps in ascertaining the cause and manner of death as a result of which the investigating agency can easily solve the crime even if it is concealed by the criminals. Like in the above mentioned case in which foul play was evident due to presence of

multiple homicidal injuries over the body; it is a duty of a Forensic expert to guide the police officials to investigate the facts in a right way. After receipt of postmortem report police investigate the matter and the whole story comes out which shocks everyone.

REFERENCES

- [1]. Pollanen MS, Chiasson DA. Fracture of the hyoid bone in strangulation: comparison of fractured and unfractured hyoids from victims of strangulation. *J Forensic Sci.* 41(1), 1996, 110-3.
- [2]. Naik SK, Patil DY. Fracture Of Hyoid Bone In Cases Of Asphyxial Deaths Resulting From Constricting Force Round The Neck. *JIAFM*, 27(3), 2005, 149-53.
- [3]. Saukko P, Knight B. *Knight's Forensic Pathology*. Boca Raton: CRC Press. 4, 2015, 384.
- [4]. Knight B. *Lawyers Guide to Forensic Medicine*. Cavendish publishing limited. London. 2, 1998, 115.
- [5]. Di Maio, D.J. & Di Maio, V.J.M. *Asphyxia*. Forensic Pathology, Boca Raton, FL: CRC Press, 2, 2001, 245–269.

How to cite this article: Vinod Kumar, Jai Prakash Soni, Vijaypal Khanagwal, Vincent Merry Dinesh Chhillar. Homicide Represented As Sudden Natural Death: A Case Report. *Int J of Allied Med Sci and Clin Res* 2016; 4(3): 569-573.

Source of Support: Nil. **Conflict of Interest:** None declared.