

Case Report :

Congenital Cystic Adenomatoid malformation of the lung masquerading as Pneumothorax

Swarnim S, Rai BK, Bidhuri N, Thakur AK

Institution and Affiliation: Post Graduate Institute of Medical Education and Research, Dr Ram Manohar Lohia Hospital, New Delhi – 110001, India. Corresponding author: Dr. Swarnim S, Mitsswarnim@gmail.com

Received: February 23, 2017. Reviewed: March, 27, 2016. Accepted: April, 25, 2017.

Abstract

Congenital Cystic Adenomatoid malformation consists of hamartomatosis or Dysplastic lung tissue mixed with more normal lung, generally confined to one lobe. This congenital pulmonary disorder occurs in 1:25,000-1:35,000 births. These lesions arise from excessive disorganised proliferation of Bronchial structures and probably results from an embryologic insult before 35th day of gestation. CCAM can be diagnosed in Utero by Ultrasonography; the median age for the diagnosis is usually 21 weeks of gestation. Patient can present in the neonatal period with significant respiratory distress, recurrent respiratory infections and pneumothorax. Patient with smaller lesions are usually asymptomatic until mid-childhood, when it can present with episodes of Recurrent or persistent pulmonary infections or chest pain.

Key words: *Congenital Cystic Adenomatoid Malformation (CCAM), Infant, premature, Infant, low birth weight*

Introduction :

Congenital cystic adenomatoid malformation (CCAM) is a rare pulmonary anomaly. It is a hamartomatous lesion characterized by a cessation of normal bronchiolar maturation, resulting in cystic overgrowth of the terminal bronchioles. We report a case of Type 1 CCAM in newborn with brief review of Literature.

Case Report :

A term male child with birth weight of 2.3 kg was born to 25 years primigravida by normal vaginal delivery at hospital. No antenatal check up was done and no antenatal USG was done. The antenatal period was uncomplicated. The child was delivered by normal vaginal route and cried immediately after birth. The child was brought to our center on Day 20 of life with complaints of respiratory distress since birth with progressive worsening and fever. Here first examination revealed RR=80/min, subcostal and intercostal retraction. He was having a SpO₂ of 85% at room air and 95% with O₂ inhalation given through nasal prong at the rate of 3 liters/min. On examination of the chest there was hyperresonant on percussion on right side with air entry decreased on right side and crepts were present on the left side. Sepsis screen was sent which was positive. The chest X-ray showed hyperlucency on right side and opacity on left side with herniation of the mediastinum to the left side suggesting tension pneumothorax of the right side with collapse & consolidation of left side.

The patient was treated with intravenous antibiotics and a chest tube insertion was done.

The patient however remained symptomatic and a repeat chest X-ray showed no improvement then CT chest was done on day 23 of life which revealed huge thin walled incomplete septated air filled right lung cysts almost completely occupying

right hemithorax with marked mediastinal shift to left and contra lateral herniation of right lung.

Finding likely represented congenital cystic adenomatoid malformation (CCAM) Type 1.

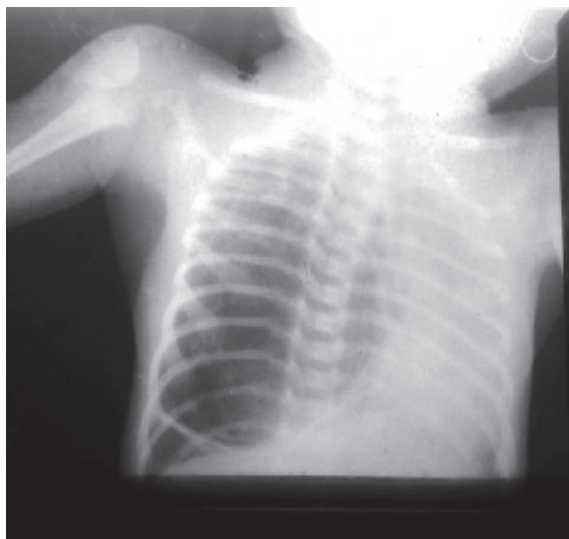

Figure 1. Infant, premature, Infant, low birth weight1Chest X-ray of the child

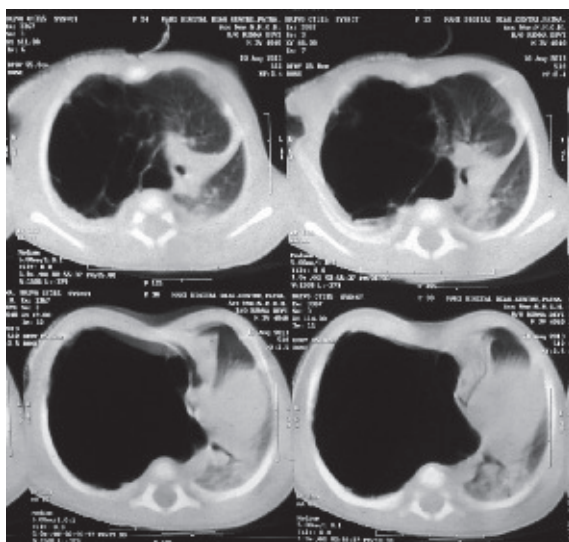


Figure 2.CT chest of the child

The patient was referred to the pediatric surgery department and managed there with lobectomy and removal of cystic lesion. Post operative course remained uneventful and patient showed marked improvement in respiratory distress and air entry.

After the surgery the child has remained in our follow up and is thriving well .

Discussion

CCAM is a rare developmental, non hereditary hamartomatous malformation of lung. The reported incidence of CCAM between 1:25000 and 1:35000 (1). Males and females are equally affected. It is usually unilateral and restricted to a single lobe (2). In upto 10% of cases additional intrapulmonary abnormalities can be found, such as renal,central nervous, gastrointestinal and cardiac defects (3) .

Based on the anatomical changes, development of human lung is subdivided into

Embryonic	3-7 weeks
Pseudoglandular	7-17 weeks
Canalicular	7-29 weeks
Saccular	24-36 weeks
Alveolar	36 Weeks to maturity

CCAM develops during the pseudo glandular and saccular period (7-35weeks) (4). Stocker, Madewell and Drake divided CCAM into three subtypes in 1977 using clinicaland pathological features based on site of origin of malformation (eg :- tracheal, bronchial, bronchiolar alveolar and Alveolar / distal acinar (4). In 2002 they added two more subtypes (type 0 and iv) (5)

Type 0-Acinar dysplasia

Type i-Multiple large cysts or a single dominate cyst

Type ii-Multiple evenly spaced cysts.

Type iii-Bulky firm mass

Type iv-Peripheral cyst type

Classification	Type 0	Type 1	Type 2	Type 3	Type 4
Frequency (%)	1-3	>65	20-25	8	10
Cyst size (maximum)	0.5 cm	0.5-10 cm	0.5-2 cm	0.3-0.5 cm	7 cm
Epithelial lining	Ciliated, pseudostratified columnar	Cuboidal cells, flattened, columnar	Ciliated cuboidal, ciliated pseudostratified	Ciliated cuboidal, columnar	Type 1&2 alveolar lining cells
Muscular wall thickness (mm)	100-500	100-300	50-100	0-50	25-100
Mucus cells	Present in all cases	Present (33% of cases)	Absent	Absent	Absent
Cartilage	Present in all cases	Present (5-10% of cases)	Absent	Absent	Rare
Skeletal muscle	Absent	Absent	Present (5% of cases)	Absent	Absent

Pathologic Features of Congenital Cystic Adenomatoid Malformation lung (according to Stocker)(4)

Prenatally diagnosed CCAM may have either of the following appearance (6)

Macrocytic - lesion with multiple or single cyst > 5 mm in diameter.

Microcytic - appears as a solid echogenic mass with size < 5 mm.

The differential diagnosis include & Lobar

Sequestration, congenital lobar emphysema, Bronchogenic cyst or congenital diaphragmatic hernia.

The condition may be detected antenatally as there may be development of fetal hydrops and maternal polyhydramnios, with anticipated mortality 100% with fetal hydrops without lung decompression in utero using resection of lobe or thoracoamniotic shunt. (7)

15 to 50% of CCAM decrease in size before birth but rarely disappears completely (8). Nearly half of the cases with apparent spontaneous 'disappearance' of antenatally diagnosed lesions on follow up require surgery.(9). Patients can present in the new born period or early infancy with respiratory distress, including cyanosis, grunting and retraction, recurrent respiratory infections and pneumothorax. The lesion may be confused with a diaphragmatic hernia. Patient with smaller lesions are usually asymptomatic until mid childhood when episodes of recurrent or persistent pulmonary infections or chest pain occurs, breath sounds may be diminished with mediastinal shift away from the lesion on physical examination.

USG, CT and MRI are used to identify the location and appearance of lung abnormality. Doppler ultra sound evaluates the blood supply and venous drainage. CCAM has its arterial and venous blood supply from the pulmonary system, where as in lung sequestration rather than pulmonary artery, the aorta is the source of blood supply and there is no communication with the bronchial tree (10).

For the lung masses, the intrauterine prognosis of the fetus is determined by fetal lung mass size(a single measurement of lung mass at the maximum diameter or by the CCAM volume rate CCVR)(19).CVR is calculated as

$$\frac{[\text{height (cm)} \times \text{width (cm)} \times \text{depth (cm)} \times 0.523]}{\text{head circumference (cm)}}$$
 for gestational normalization.

A CVR > 1.6 is predictive of increased risk of hydrops.

Antenatal intervention in severely affected infants is controversial but can include excision of the lobe for microcystic lesions, aspiration of macrocystic lesion, and rarely open fetal surgery (18).Delivery should be conducted at specialized centre in antenatally diagnosed cases.

In the post natal period, surgery is indicated for symptomatic patients. If the patient is asymptomatic, surgery is postponed but CT Chest

is done within 1 month postnatally in all cases to delineate the thoracic lesion, demonstrate any connection with the Tracheobronchial Tree and to evaluate the blood supply.

Sarcomatous and carcinomatous differentiation has been described in patients with CCAM. so surgical resection by 1 year of age is recommended to limit malignant potential.(18).

The mortality rate is <10% and long term outcome is very good for surgically managed symptomatic patients.

References:

1. Laberge JM, Flageole H, Pugash D, et al. Outcome of the prenatally diagnosed congenitalcystic adenomatoid lung malformation: a Canadian experience. *Fetal Diagn Ther* 2001; 16: 178-186.
2. Davenport M, Warne SA, Cacciaguerra S, et al. Current outcome of antenally diagnosed cysticlun disease. *J Pediatr Surg* 2004; 39: 549-556.
3. Stocker JT. Congenital and developmental diseases. In: Dail DH, Hammer SP, editors. *Pulmonary pathology*, New York: Springer. 1994; 2nd ed: 174-180.
4. Stocker JT, Madewell JE, Drake RM. Congenital cystic adenomatoid malformation of the lung. Classification and morphologic spectrum. *Hum Pathol* 1977; 8: 155-171.
5. Stocker JT. Congenital pulmonary airway malformation: a new name for and an expandedclassification of con-genital cystic adenomatous malformation of the lung. *Histopathology* 2002;41(Suppl 2): 424-431.
6. Adzick NS, Harrison MR, Glick PL, et al. Fetal cystic adenomatoid malformation: prenatal diagnosis and natu-ral history. *J Pediatr Surg* 1985; 20: 483-488.
7. Gornall AS, Budd JL, Draper ES, et al.

- Congenital cystic adenomatoid malformation : accuracy of prenatal diagnosis, prevalence and outcome in a general population. *Prenat Diagn* 2003; 23: 997-1002.
8. Ozcan C, Celik A, Ural Z, et al. Primary pulmonary
 9. rhabdomyosarcoma arising within cystic adenomatoid malformation: a case report and review of the literature. *J Pediatr Surg* 2001; 36: 1062-1065.
 10. Calvert JK, Boyd PA, Chamberlain PC, et al. Outcome of antenatally suspected congenital cystic adenomatoid malformation of the lung: 10 years' experience 1991-2001. *Arch Dis Child Fetal Neonatal Ed* 2006; 91:F26-28.
 11. Cass DL, Crombleholme TM, Howell LJ, et al. Cystic lung lesions with systemic arterial blood supply: a hybrid of congenital cystic adenomatoid malformation and bronchopulmonary sequestration. *J Pediatr Surg* 1997; 32: 986-990.
 12. Calvert JK, Lakhoo K. Antenatally suspected congenital cystic adenomatoid malformation of the lung: postnatal investigation and timing of surgery. *J Pediatr Surg* 2007; 42: 411-414.
 13. Giardikis S, Didilis V, Polychronidis A, et al. Spontaneous pneumothorax resulting from congenital cystic adenomatoid malformation in a preterm infant: case report and literature review. *Eur J Pediatr Surg* 2002; 12: 195-198.
 14. Boon D, Llewellyn T, Rushton P. A strange case of a tension pneumothorax. *Emerg Med J* 2002; 19:470-471.
 15. Douglas R W., Hedrick H L, Liechty K W, Flake A W, Johnson M P, Bebbington M, et al. Cystic adenomatoid malformation of the lung: Review of genetics, prenatal diagnosis, and in utero treatment. *Amer J Med Genetics* 2006; 140: 151-155.
 16. Ribet ME, Copin MC, Soots JG, Gosselin BH. Bronchoalveolar carcinoma and congenital cystic adenomatoid malformation. *Ann Thorac Surg* 1995; 60: 1126-1128.
 17. Chetcuti PA, Crabbe DC. CAM lungs: the conservative approach. *Arch Dis Child Fetal Neonatal Ed* 2006; 91:F463-464.
 18. Nelson Text book of Pediatrics 19th edition.
 19. Crombleholme TM, Coleman BM, Hedrick H, et al. Cystic adenomatoid malformation volume ratio predicts outcome in prenatally diagnosed Cystic adenomatoid malformation of the lung. *J Pediatr Surg* 2002; 37:331-338.