

Foreign Body (Coin) in the posterior choana of nasal cavity of a child- A rare case report

Devendra Maurya¹, Harendra Kumar Gautam², Surendra Kumar Kannaujia³, Astha Singh^{4,*}

^{1,4}Junior Resident, ^{2,3}Associate Professor, Dept. of ENT, Ganesh Shankar Vidyarthi Memorial Medical College, Kanpur, Uttar Pradesh, India

***Corresponding Author:**

Email: astha.singh03@yahoo.com

Abstract

Cases of foreign bodies in the aero digestive tract are common in children. But their presence in posterior choana is rarely encountered as they present with vague set of symptoms. We encountered a female child with history of coin ingestion without any symptoms like nasal blockade and mouth breathing. On X- ray it was found to be in posterior choana and was removed immediately. Hence any suspected foreign bodies in aerodigestive tract should be thoroughly evaluated for their location.

Keywords: Foreign body, Coin & posterior choana.

Introduction

Foreign body ingestion is a common entity in children.¹ The fate of the ingested foreign body is that it can either pass further down the aerodigestive tract, can be expelled by cough or can get stuck at the narrow parts of the upper aero-digestive tracts.² The common site for the foreign body to get stuck is crico-oesophageal junction. Ingested foreign body to get lodged in the posterior choana is a rare entity as the direction of movement is against gravity.³ Impaction of the FB in the nasopharynx may result due to failed attempt in removing it or due to dislodgement of the FB from initial site of impaction by vomiting or cough. Here we are going to discuss a case of foreign body in the posterior choana of a 7 year old girl, how it presented to us and how we managed the case in emergency.

Case Report

A 7 year old girl was brought to the emergency department with a history of accidental coin ingestion through the nose two days back with complaint of pain around the nose. On examination of the child, there was no Stridor or chest retraction. The oral cavity and oropharynx were normal and no foreign body was found. Anterior rhinoscopy showed minimal mucoid discharge in the nose. A CT Paranasal sinus was ordered to confirm the presence and position of the foreign body. The CT scan showed the presence that the coin was lodged in posterior choana in saggital plane parallel to septum of nose which was quite unusual. The pictures of the CT scan are shown as (Fig. 1 & 2).

Immediately when the position of the coin was located with the help of CT PNS, the girl was posted for removal of the FB under general anaesthesia. The patient was kept in supine position with head end lowered. With the help of thudicum's nasal speculum and blakesley forceps coin was pushed from posterior choana to oropharynx and coin was held and removed

from oral cavity. There were no post operative complications and the patient was discharged on the next day.

Discussion

The presence of the foreign body in posterior choana is a rare entity as the normal route for an aero digestive foreign body is mouth. In case of foreign body nasopharynx, it is nose.⁴ In our case, the foreign body (coin) was present in posterior choana and the mode of entry of foreign body is from nose itself. There are literatures saying ingested foreign bodies can reach the nasopharynx by regurgitation/ vomiting/ coughing or by failed attempt to remove the foreign body by parents or physicians.⁵ Patients with nasopharyngeal foreign body present with symptoms like difficulty in breathing, nasal obstruction, nasal bleeding or nasal discharge. Diagnosis of the case is not challenging when there is clear history but sometimes when there are no nasal symptoms as in our case only radiological investigations can guide us to the diagnosis.⁷ Removal of the foreign body from nasopharynx is always safe to be done with head end low position so that the risk of the foreign body to enter the lower airway is avoided.⁶

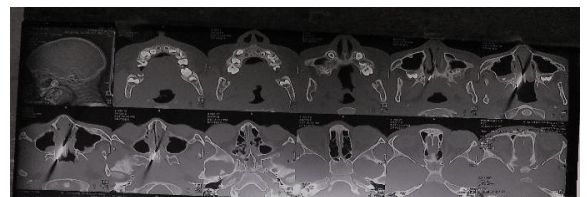


Fig. 1: Showing axial view of CT paranasal sinus with a radiopaque shadow parallel to septum posteriorly

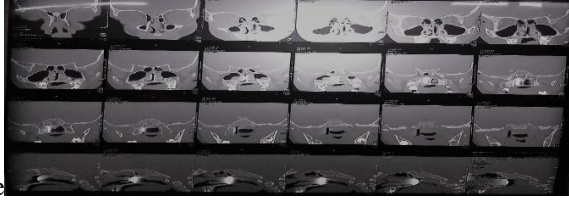

Fig. 2: showing coronal view of CT paranasal sinus with a radiopaque shadow in between the septum & inferior turbinate at the level of posterior choana

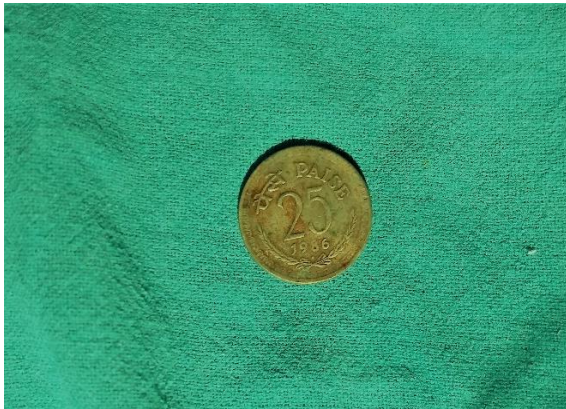

Fig. 3: removed foreign body coin from posterior choana

Conclusion

From the discussion of the above case and review of previous literature we come to the conclusion that examination of posterior choana of nasal cavity and radiological evaluation is necessary in cases of suspected foreign bodies in aero digestive tract. Immediate removal is indicated with the patient in supine position with head end down.

References

1. Krishnappa BD. Endoscopic removal of an unusual foreign body in the nasopharynx in a 3 year old child. *Int J Head Neck Surg* 2013;4(3):140-41.
2. Jagdish Kumar. Nasopharyngeal Foreign Body in a Young Child. *Indian J Otolaryngol Head Neck Surg* 2011;63(3):285-86.
3. Satheesh Bhandary, Biniyam Kolathingal, Vadish Bhat, Balakrishna Padubidri Srinivas. Common Foreign Body, Unusual Site. *Otolaryngol Head Neck Surg* 2011;145(6):1060-61.
4. Kiger J, Brenkert T, Losek J (2008) Nasal foreign body removal in children. *Pediatr Emerg Care* 24: 785-792.
5. Pallab Kumar Majumder, AK Sinha, PB Mookherje, SN Ganguly. An unusual foreign body (10 N. P. COIN) in nasopharynx. *Indian J Otolaryngol Head Neck Surg* 1999;52(1):93.
6. Manish Gupta (2014) Endoscopic removal of an unusual foreign body from nasopharynx. *Research* 1:871.
7. Raman Wadhera, SP Gulati, Ajay Garg, Anju Ghai. Two rare case reports of nasopharyngeal foreign bodies: bobbin and safety pin. *Int J Pediatr Otorhinolaryngol* 2008;3(1):14-6.