


**PEDIATRIC UROLOGY CASE REPORTS**

ISSN 2148-2969

<http://www.pediatricurologycasereports.com>**Post traumatic isolated and complete bladder neck horizontal transection: A case report and literature review***Ngu Ing Soon**Department of Urology, Sarawak General Hospital, Kuching, Malaysia***ABSTRACT**

Isolated bladder neck horizontal transection without bladder or prostatic involvement is very rare in pediatric age group. To our knowledge, this is the first case of such trauma reported in Malaysia. In this article, we present a case of primary suprapubic catheter insertion with delayed vesicoprostatic urethral anastomosis in the treatment of complete bladder neck horizontal transection.

Key Words: Bladder neck, trauma, pelvic fracture, vesicoprostatic urethral anastomosis.

Copyright © 2019 [pediatricurologycasereports.com](http://www.pediatricurologycasereports.com)

Correspondence: Dr. Ngu Ing Soon

Department of Urology, Sarawak General Hospital, Kuching, Malaysia

E mail: ngu_ingsoon@yahoo.com

ORCID ID: <https://orcid.org/0000-0002-7432-8549>

Received 2019-09-05, Accepted 2019-10-07

Publication Date 2019-11-01

Introduction

Complete bladder neck distraction injury is a well-recognized consequence of pelvic fracture related trauma, especially among pediatric age group. However, isolated bladder neck horizontal transection without bladder or prostatic involvement is very rare [1-5]. To our knowledge, this is the first case of such trauma reported in Malaysia. Therefore, its management is poorly defined on top of the controversial timing of repair. Herein we present a case of primary suprapubic catheter (SPC) insertion with delayed vesicoprostatic urethral anastomosis in the treatment of complete bladder neck horizontal transection.

Case report

A 5-year-old boy who was a pedestrian, was knocked down by a car which was moving at low speed when he attempted to cross a road. Following trauma, he refused to bear weight on his right lower limb and could not pass urine. Pelvic X-ray noted right superior and inferior pubic rami fracture.

CT abdomen and pelvis were performed on the same day. It revealed hemoperitoneum at bilateral paracolic gutters as well as posterior urethral rupture with distraction from the bladder base of 4 cm gap. SPC was inserted at district hospital and subsequently transferred to the tertiary hospital which provides pediatric surgical care. Cystogram and retrograde urethrogram showed complete transection at the urinary bladder neck and extraperitoneal contrast leakage inferior to the urinary bladder. Primary realignment was not successful due to inability to visualize urethral opening in both

antegrade and retrograde urethroscopy (Fig. 1).

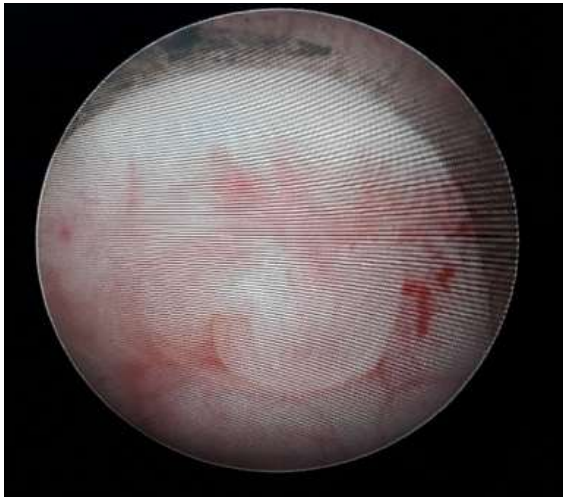


Fig. 1. Obliterated bladder neck from antegrade cystoscopy.

Considering the significant pelvic hematoma and bleeding, delayed vesicourethral anastomosis was done 4 months after trauma. Exploration was performed in supine position via a modified pfannenstiell incision. Pre-vesical space was adherent and therefore peritoneum was opened to have better resection. Intra-operatively noted fibrotic scar tissue between the bladder neck and blind-ending prostatic urethra just deep to the symphysis pubis while the distance between them was 1cm. Bladder neck was identified by the insertion of urethral sound and cut down from the retropubic space was done. The obliterated proximal end of the prostatic urethra was identified with the illumination of urethroscopic light as well as urethral sound and then dissected away from the surrounding fibrotic tissue (Fig. 2). Bladder neck to prostatic urethral anastomosis was done using PDS suture, starting from the posterior wall. The omentum could not be mobilized to wrap anastomosis as it was still not well-developed.

Thus, bladder was anchored to the prepubic fascia to prevent excessive tension on the anastomosis and for better continence.

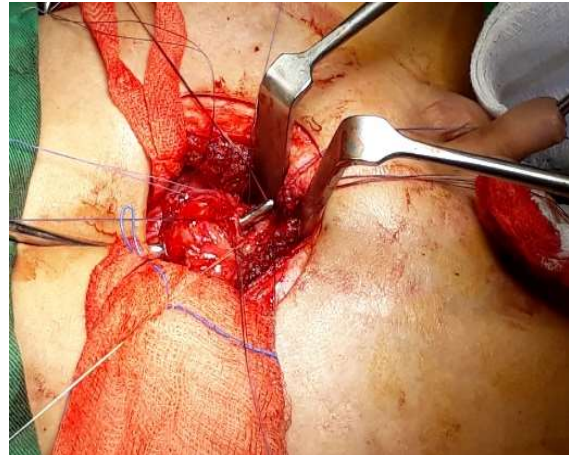

Fig. 2. Identification of bladder neck and prostatic urethra with different urethral sound.

Post-operative recovery was uneventful with the urethral catheter removed after 4 weeks. He was continent with good uroflow and no postvoid residual urine at post-operative 8 months (Fig. 3) as well as preservation of erection.

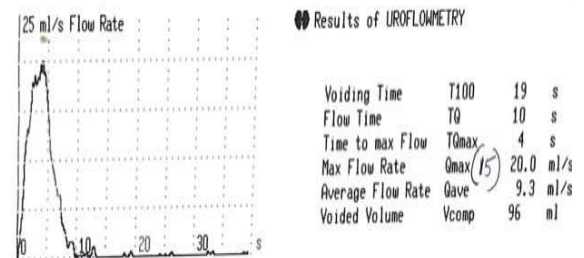


Fig. 3. Uroflowmetry 6 months post-operation.

Discussion

The posterior urethral injury is uncommon in pediatric age group as their sacroiliac joint and symphysis pubis are more elastic in addition to the greater pelvic bone plasticity. Injuries at the level of the bladder neck or through the prostate occur in 15–57% of childhood pelvic fracture urethral injuries [1]. Bladder neck

injuries are usually longitudinal and may extend into the prostatic or sub-prostatic urethra [2]. The risk of complete bladder neck distraction injury is more common in children than in adults. Mundy AR and Andrich DE suggested new types of adult bladder neck injuries such as trapped prostate or blow out of the anterior aspect of the prostate [3]. Gite et al. [4] reported the first case of post traumatic isolated bladder neck transection in children. The case presented here is the second patient with transverse bladder neck transection without bladder or prostate injury. In addition, this type of injury cannot be placed in the existing classification system. The proposed mechanism is due to the intra-abdominal location of the bladder which is more mobile and smaller as well as cranially placed prostate which is fixed [5].

According to Sawant et al., early repair of the bladder neck injury was preferred over delayed repair because of the lower stricture rate of 16.6% compared to 37.5% in those underwent delayed repair. Other considerations that should be taken into account include urinary extravasation causing pelvic urinoma, abscess, and osteomyelitis or necrotizing fasciitis and incontinence rate post-operatively [1]. The strategy of suprapubic cystostomy and delayed anastomosis were adopted in this case to achieve urinary diversion whilst avoiding disruption of fracture hematoma and subsequent bleeding and infection. Moreover, well-planned elective surgery can be performed for any resultant stricture in a stable patient by an experienced urologist later. However, if there is any concomitant rectal or vaginal injury, an immediate laparotomy and primary repair are mandatory [5].

Urinary incontinence and erectile dysfunction are common additional problems with pelvic fracture [4]. Despite having complete

transection of the bladder neck, our patient did not develop any incontinence, impotence or stricture post-operatively at 8 months of follow up.

Conclusion

The sphincter mechanism holds the rupture of the bladder neck open and the injury never heals spontaneously. We described this particular type of bladder neck injury with its repair technique seldom discussed in the literature, especially of this total transabdominal approach.

Compliance with ethical statements

Conflicts of Interest: None.

Financial disclosure: None.

Consent: All photos were taken with parental consent.

References

- [1] Sawant AS, Kapadnis LA, Kumar V, Pawar P, Tamhankar AS. Paediatric Post-Traumatic Bladder Neck Distraction Injury: Case Series. *J Clin Diagn Res JCDR.* 2017;11(2):PR03–4.
- [2] Andrich DE, Day AC, Mundy AR. Proposed mechanisms of lower urinary tract injury in fractures of the pelvic ring. *BJU Int.* 2007;100(3):567-73.
- [3] Mundy AR, Andrich DE. Pelvic fracture-related injuries of the bladder neck and prostate: their nature, cause and management. *BJU Int.* 2010;105(9):1302-8.
- [4] Gite VA, Singal A, Nikose JV, Jain HM. Post traumatic isolated bladder neck transection: Unreported and undescribed injury. *Urol Case Rep.* 2017;17:67–69.

- [5] Barratt RC, Bernard J, Mundy AR, Greenwell TJ. Pelvic fracture urethral injury in males—mechanisms of injury, management options and outcomes. *Transl Androl Urol.* 2018;7(1):S29-S62–S62.

