

Nasal Polyp (Nasa Arsha) Management Through Ayurveda: A Single Case Study

Dr. Shyam Kumar Sah¹, Dr. Deeraj BC², Dr. Ashwini MJ³

¹Research Fellow, ²Associate Professor, ³Professor

^{1,2,3}Sri Dharmasthala Manjunatheshwara College of Ayurveda and Hospital, Hassan, Karnataka. India

How to cite this paper: Dr. Shyam Kumar Sah | Dr. Deeraj BC | Dr. Ashwini MJ "Nasal Polyp (Nasa Arsha) Management Through Ayurveda: A Single Case Study" Published in International Journal of Trend in Scientific Research and Development (ijtsrd), ISSN: 2456-6470, Volume-3 | Issue-4, June 2019, pp.501-504, URL: <https://www.ijtsrd.com/papers/ijtsrd23812.pdf>



IJTSRD23812

Copyright © 2019 by author(s) and International Journal of Trend in Scientific Research and Development Journal. This is an Open Access article distributed under the terms of the Creative Commons Attribution License (CC BY 4.0) (<http://creativecommons.org/licenses/by/4.0>)



manifestation of Rhinosinusitis, Cystic fibrosis, Allergic fungal sinusitis, Samter's triad (triad of nasal polyp, asthma and aspirin intolerance), Young's syndrome, Churg-Strauss syndrome, Nasal mastocytosis and Neoplasms.⁶

Small nasal polyps may not cause symptoms. Larger growths or groups of nasal polyps can block the nasal passages and lead to breathing problems, a lost sense of smell and taste, facial pain or headache, a sense of pressure over forehead and face, frequent infections and Snoring.⁷ Nasal polyps can affect anyone, but they are more common in male adults with male-female ratio of 4:1. Polyps can be graded into four stages according to their size⁸:

- Stage I: Limited to the extent of middle turbinate.
- Stage II: Extending beyond the limit of middle turbinate.
- Stage III: Approaching to inferior turbinate.
- Stage IV: Going up to the floor of nose.

Management of nasal polyp forms a large part of the workload for the otolaryngologist. Medical management is the choice for Ethmoidal Polyps.⁹ Medications can help to shrink or eliminate nasal polyps, but surgery is sometimes needed to remove them. Even after successful treatment, recurrence rate is high.

ABSTRACT

Nasal polyp is a chronic inflammatory disease affecting about 1–4% of the general population.¹ Nasal polyps are fleshy benign growth that develop in the mucosal lining of the nasal passage and paranasal sinuses. Polyps vary in size and having shining pink colour and shaped like tear drops.^{2,3} The exact etiology remains unclear but it is known to have associations with allergy, asthma, infection, cystic fibrosis and aspirin sensitivity. The common features of the disease are nasal obstruction, anosmia, rhinorrhoea, post nasal drip and less commonly facial pain.⁴ In Ayurveda; it is closely related to nasa arsha. Nasa arsha is a Kapha vata vyadhi located in Urdwanga which is a kapha sthaan.⁵ In this study, a single case 55 years old male patient presented with frequent episodes of nasal obstruction, anosmia mouth breathing and sometimes headache since six months was taken for study. An approach was made to treat the patient by sodhana, shamana and sthanika chikitsa with a positive clinical response. Local therapy was the application of Gunja lepa over polyps. This study aimed at introducing a new treatment modality with new formulation.

Keywords: Nasal polyp; Nasa arsha; Sodhana; Shamana; Sthanika chikitsa and Gunja lepa

1. INTRODUCTION

Nasal polyps are soft, painless, benign growths arising from the mucosa on the lining of nasal passages or sinuses. They hang down like teardrops or grapes. Nasal polyps are traditionally divided into two types- Antrochoanal polyp and Ethmoidal polyps. Although having an uncertain etiology, they result from chronic

In Ayurveda, it is closely related to Nasa arsha. This is a condition where patient feels nasal blockage. Sushruta had explained 4 types of nasarsha: Vataja, Pittaja, Kaphaja and Sannipataja as well as 4 types of treatments- Aushadhi, Ksharkarma, Agnikarma and Shastrakarma.¹⁰ In this study aushadha karma had been followed to treat Nasa arsha.

Gunja (A brief introduction):¹¹

Gunja (*Abrus precatorius* Linn.), a well known plant of Ayurveda under Upavisha group (sub/semi poisonous group), is being used extensively in different formulations with great therapeutic significance and is being advocated to use in various diseases like Indralupta (alopecia), Shotha (edema), Krimi (helianthus), Kustha (skin diseases), Kandu (itching), Prameha (urinary disorders) etc. After proper samaskar known as shodhana (purification). Glycyrrhizin, Triterpene glycosides, pinitol and alkaloids such as abrine, hepaphotone, choline and precatorine are the principle chemical constituents of the plants. Among all varieties, **sweta gunja** was taken for study and purified by putting it into hot milk for 24 hours. Then paste was prepared by rubbing the seeds on stone. That paste was applied over the nasal polyp.



Consent:

Informed consent was taken prior to case study.

Case Study

A 55 year old male patient (OP-154752) visited ENT OPD on 29/09/2018 of Sri Dharmasthala Manjunatheshwara College of Ayurveda and Hospital, Hassan, Karnataka, with chief complaints of B/L nasal blockage, difficulty in breathing and irritation in throat since 10years. The symptoms were aggravated during evening time and on exposure to dusts and cold. His personality was average built; body weight was 68 kg and belonging to middle class socioeconomic status. Occupationally, he was a farmer. No significant family history and personal history identified. He consulted many allopathic ENT surgeons where he was diagnosed as **Right Ethmoidal Polyp Grade IV with chronic sinusitis**. He was treated by antibiotics, NSAIDs and steroids nasal spray but got symptomatic relief only. Further he was advised for surgical intervention polypectomy. For above said complaints he was admitted (IP- 033541) here on the same day for further management. There was no history of diabetes mellitus or hypertension. His vitals were within normal limits. On general examination, there was no pallor, icterus, clubbing of nails, oedema or lymphadenopathy noted. No CNS abnormalities noted on through examination.

Investigations:

- Routine haematological and urine investigations were carried out and findings were not of any pathological significance.
- Endoscopic and mobile camera image of the polyp before and after treatment in the minor OT were taken.

Treatment Protocol:

1st Day:

- Amapachanna with Chitrakadivati 2 tablets with Panchakolaphanta 100ml tid followed by Sthanika Avagundana with Dhanyaka, Haridra and Tulasi in Triphala kashaya over fronto-maxillary region.

2nd Day:

- Sadhyovireachana with Nimbamritadi Erand taila 60ml followed by Triphala kashaya 100ml was given on empty stomach at 8 a.m.
- Sips of hot water and Jeera jala were also given.
- Sthanika avagundana was given at 4 p.m.

3rd Day:

- Mukha abhyanga with Asanbilwadi taila followed swedana karma.
- Marsha nasya with Shikari taila 12-12 drops in each nostril followed by haridra and ghrita dhumapana in the morning on empty stomach.

- Sthanika Avagundana was given in the afternoon.
- Purified Sweta Gunja Lepa over the polyp inside right nostrils on alternate day was applied.
- Internal medication like tab. Laghu Sutsekhsar Vati 1 BD, Haridrakhanda 1 tsf BD with hot water and Pippalyasava 3 tsf BD after food with water were given. These regimens were continued for 7days.

10th Day:

Patient was discharged and advised to continue tab. Laghu Sutsekhsar Vati 1 BD, Haridrakhanda 1 tsf BD with hot water and Pippalyasava 3 tsf BD after food for 15 days as well as to avoid apathy and aggravating factors. **(Picture-1)**

1st Follow up:

After 15th day patient came to ENT OPD with mild relieved symptoms **(Grade III)**. Gunja lepa was applied again over the polyp. He was advised to continue the same medications and follow up after 15 days. **(Picture-2)**

2nd Follow up:

He came to ENT OPD with no blockage of nasal passage, no sinuses tenderness and reduced in the size of the polyp **(Grade III)**. Again Gunja lepa was applied over the polyp. He was advised to follow up after 15 days with no internal medications. **(Picture-3)**

3rd follow up:

Patient has no any complaints **(Grade II)**. Gunja lepa was applied on the polyp and advised to follow up after 1 month interval. **(Picture-4)**

4th and 5th follow up:

Patient was almost normal **(Grade I)**. Gunja lepa was applied on the polyp on 4th **(Picture-5)** and 5th **(Picture-6)** follow up on 1 month interval. The size of the polyp was almost atrophied on 5th follow up.

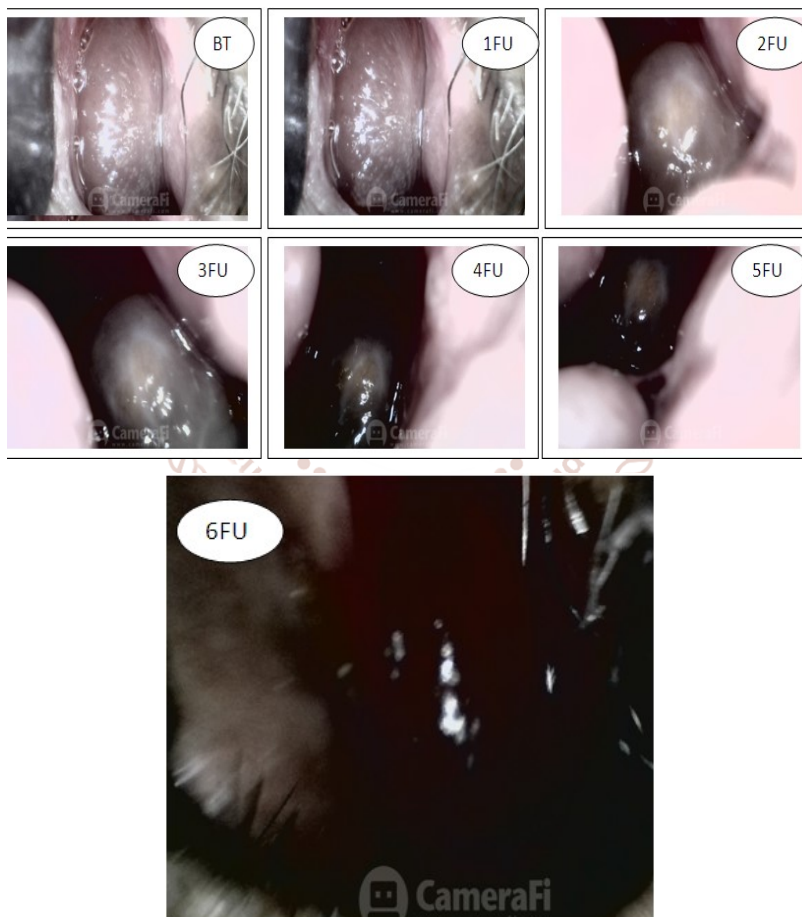
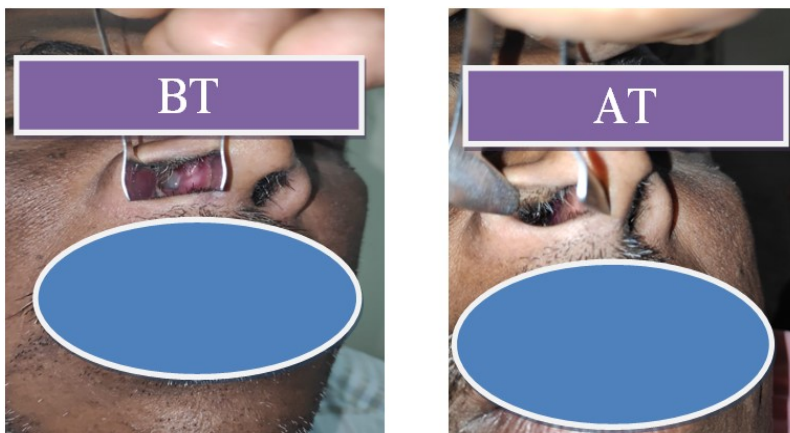
The patient visited to ENT OPD 2 months later after the last follow up with **no polyp** in right nostril noticed through anterior rhinoscopy. **(Picture-7)**

Results:

Significant changes in signs and symptoms were noticed before treatment and after treatment with short course duration of 10 days. Patient felt good response after 2nd day application of Gunja lepa. On the day of discharge-10th day, he was happy and feeling better. On regular follow up the sign and symptoms reduced progressively and on 5th follow up, the polyp was almost atrophied.

Parameters used BT and AT

Parameters	BT	DT 10 th day	1 st FU	2 nd FU	3 rd FU	4 th & 5 th FU	AT
Nasal Blockage	+	+	+	-	-	-	-
Mouth breathing	+	+	+	-	-	-	-
Smell perception	-	-	-	+	+	+	+
Polyp size	+ Gr-IV	+ Gr-IV	+ Gr-III	+ Gr-III	+ Gr-II	+ Gr-I	- No Polyp



Discussion:

Ayurveda believes in treating the disease at its root cause from within. Sodhana and Shamana both therapies were given to the patient. Sadhyovirechana with Nimbamritadi Erand taila detoxifies the body and removes the vitiated pitta and kapha doshas from the kosta. Nasya karma with Shikari taila was instilled into both nostrils and was expected to strengthen the vital functions of the sense organs by its unique mode of action through Shringataka marma. Sthanika avagundana helped to open the Vatahava shrotas and lightened the head. The ingredients used for avagundana

Dhanyaka, Haridra and Tulasi in Triphala kashaya was supposed to pacify vitiated vata-kapha Doshas. The active principle in gunja lepa is Abrin which contains Toxalbumin and Glycosides, a water soluble glycoprotein inhibits protein synthesis and causes agglutination, hemolysis and cell destruction. The internal medications also helped to pacify the vitiated Doshas and brought into the equilibrium state. The combination of both sodhana and shamana therapies as well as local gunja lepa was acted synergistically to combat against the vitiated tridoshas in pathology of Nasa arsha.

Conclusion:

Nasal polyp i.e. Nasa arsha is a chronic inflammatory disease. Ayurveda believes in cleansing the body and pacifying the tridoshas from the roots by using unique treatment modalities such as sodhana, shamana and sthanika chikitsa. These treatment approaches create a balanced physiology which regress the size of nasal polyps and thus making the patient symptom free by non invasive method. Ayurveda creates a new hope for treatment of nasal polyps (Nasa arsha) for this era.

References

- [1] Epidemiology and differentia diagnosis of nasal polyps-NCBI
INH <https://www.ncbi.nlm.nih.gov/pmc/articles/PMC3899526/>
- [2] <https://www.medicinenet.com/script/main/art.asp?articlekey=114176>
- [3] <https://www.healthline.com/health/nasal-polyps>
- [4] Bansal Mohan, Disease of Ear, Nose & Throat with Head & Neck Surgery. 6th ed. New Delhi; Jaypee Brothers Medical Publishers (P) Ltd. 2018. 13:335
- [5] Sushruta. Uttarantra. Shastri Kaviraj Ambika Datta, Sushruta Samhita, 7th ed. Varanasi: Chaukhambha Viswabhharati; 1990. 22:111
- [6] Bansal Mohan, Disease of Ear, Nose & Throat with Head & Neck Surgery. 6th ed. New Delhi; Jaypee Brothers Medical Publishers (P) Ltd. 2018. 13:335
- [7] <https://www.mayoclinic.org/diseases-conditions/nasal-polyps/symptoms-causes/syc-20351888>
- [8] Bansal Mohan, Disease of Ear, Nose & Throat with Head & Neck Surgery. 6th ed. New Delhi; Jaypee Brothers Medical Publishers (P) Ltd. 2018. 13:335
- [9] Bansal Mohan, Disease of Ear, Nose & Throat with Head & Neck Surgery. 6th ed. New Delhi; Jaypee Brothers Medical Publishers (P) Ltd. 2018. 13:335
- [10] Sushruta. Uttarantra. Shastri Kaviraj Ambika Datta, Sushruta Samhita, 7th ed. Varanasi: Chaukhambha Viswabhharati; 1990. 22:117
- [11] Roy Sudipta, Acharya Rabinarayan, Shukla V J. Shodhana (Processing) of Gunja (Abrus precatorius Linn.) Seeds with Godugdha (Cow's milk); a pharmaceutical analysis. International Journal of Ayurvedic Medicine, 2012, 3(2), 68-75

