



Effect of Methanol Leaf Extract of *Vitex Doniana* on Cadmium Chloride-Induced Toxicity in Kidney and Liver Tissues of Male Wistar Rats

Olajide, J. E., Sanni, M., Omattah, G. O.

Department of Biochemistry, Faculty of Natural Sciences,
Kogi State University, Anyigba, Kogi State, Nigeria

ABSTRACT

The aim of this study was to investigate the effects of methanol leaf extract of *Vitex doniana* (MEVd) on Cadmium chloride - induced toxicity in the liver and kidney of male Wistar rats was investigated. Twenty five male Wistar rats weighing $171.87 \pm 7.86\text{g}$ were acclimatized for two weeks and subsequently randomized into five groups: Group 1 rats were administered daily 1 ml distilled water (control group); group 2 were administered Cadmium chloride (10 mg/kg b.w.) only; groups 3 and 4 were administered MEVd (200 and 400 mg/kg b.w. respectively) six hours prior administration of Cd (10 mg Cd/kg b.w.) and group 5 rats were administered MEVd (400 mg/kg/b.w.) only. The experiment lasted six weeks and all administration was carried out orally. The final body weights of the rats were recorded at the end of the experiment and afterwards the rats were sacrificed, blood was collected and the serum was subsequently prepared. The kidneys and liver were excised, weighed and then stored in 10% formalin for histological examination. The serum was used for the determination of urea, creatinine, Na^+ , K^+ , and Cl^- concentrations, aspartate aminotransferase (AST) and alanine aminotransferase (ALT) activities and total bilirubin (T-Bil) concentration. The results showed that exposure of the rats to Cd significantly ($p < 0.05$) increased kidney weight, serum urea, creatinine, Na^+ , K^+ , Cl^- and total bilirubin concentrations as well as serum ALT and AST activities. Cd-induced toxicity also caused severe necrosis of the tubular epithelial cells in the nephrons and degeneration of the hepatocytes. Although both doses of the plant extract significantly ameliorated these changes, the amelioration at 200 mg/kg body weight of the extract compared well with the control in most of the parameters investigated. In

conclusion, the oral administration of methanol leaf extract of *Vitex doniana* ameliorated the Cd-induced toxicity related biochemical parameters and histological changes in the rats.

Keyword: Cadmium chloride, Toxicity, Liver, Kidney, *Vitex doniana*, Ameliorate

INTRODUCTION

Cadmium (Cd) is one of the most notorious toxic heavy metals. It is one of the major toxic environmental and industrial pollutants, obtained through consumption of Cd contaminated foods, drinking water, inhaled air, cigarette or from ingestion of polluted soil and dust (Jarup *et al.*, 2000). Cd is generally used as components of pigments, plastic stabilizers, alloys, Nickel-Cd batteries, and in welding and electroplating in industries. It is also present in tobacco grown on contaminated soil (Ohta *et al.* 2000; Washington *et al.*, 2006). Cd is spread from its natural sources into the atmosphere through volcanic activity, forest fires, and wind-blown soil particles. Other sources of Cd include phosphate fertilizers, which may possess high levels of Cd based on the origin of the rock, and also the use of contaminated sewage sludge as soil additive (Waisberg *et al.*, 2003). Being that polyvinyl chloride (PVC) contains cadmium, toys made of PVC are potentially toxic to children. Owing to its long biological half-life of 15–30 years, the rate of disintegration of cadmium is very low; and as a result, cadmium accumulates in the blood, kidneys, liver and reproductive organs, such as placenta, testis as well as the ovaries, making it a hazardous toxic metal (Navaneethan and Rasool, 2014). However, the kidney is the primary target organ for chronic low-level exposure to Cd and is reflected in a number of

renal function parameters including tubular necrosis (Satarug *et al.*, 2010). This may eventually result to end-stage renal failure, abnormal blood pressure, diabetic manifestations and osteoporosis (Satarug and Moore, 2004).

In recent time, there is an increasing interest in herbal formulations because of their potent antioxidant properties. Higher intake of vegetables, fruits and whole grains that are rich in antioxidants have been associated to reduce risk of several diseases, including cancer, cardiac diseases, chronic inflammation and many degenerative diseases. *Vitex doniana* (*V. doniana*), a member of the Verbanaceae family is a perennial shrub with wide distribution in tropical West Africa such as Nigeria, and extends to some East African countries and in the savannah and high rainfall areas (Atawodi *et al.*, 2003). *V. doniana* leaves are consumed in Nigeria as vegetables which are valued sources of protective foods and it is of great benefits for the maintenance of good health and disease prevention (Nnamani *et al.*, 2007). In ethno-medicine, *V. doniana* leaf is utilized in the management and treatment of many diseases. It is employed in the treatment of stomach and rheumatic pains, inflammatory disorders, diarrhoea and dysentery (Iwueke *et al.*, 2006). According to Iwu (1993), the leaves and roots of *V. doniana* are also utilized in the treatment of nausea, colic and epilepsy. The plant has been utilized as medication for liver disease, anodyne, stiffness, leprosy, backache, hemiplegia, conjunctivitis, rash, measles, rachitis and febrifuge. It also serve as tonic galactagogue to aid milk production in nursing mothers, sedative, digestive regulator and treatment of eye and kidney problems, and as supplement for lack of vitamin A and B (Burkill, 2000). A number of authors have evaluated the medicinal/pharmacological application of *Vitex doniana*: antioxidant and hypoglycaemic (Yakubu *et al.*, 2013) antimicrobial (Nwachukwu and Uzoeto, 2010), anti-inflammatory and analgesic (Iwueke *et al.*, 2006) effects. Phytochemical reports abound to show that *V. doniana* extracts contains secondary metabolites and other phytochemicals such as alkaloids, saponins, tannins, anthraquinones, flavonoids, terpenoids which account for its therapeutic potential (Agbafor and Nwachukwu, 2011). The aim of this study was to investigate the ameliorative effect of methanol leaf extract of *Vitex doniana* in Cadmium chloride-induced toxicity in the kidney and liver of male Wistar rats.

Materials and methods

Chemicals, reagents and equipment

Reagents: The reagents used for this study was purchased from reputable companies. Reagent kits for urea, creatinine, ALT, AST and bilirubin assays are products of Randox Laboratories Ltd., United Kingdom. Reagent sets for sodium, potassium and chloride concentrations assays are products of Teco Diagnostics, U.S.A.

Collection and extraction of *Vitex doniana* leaves

Fresh leaves of *Vitex doniana* were collected in the vicinity of Kogi State University Anyigba, Nigeria. They were thereafter authenticated in the Department of Biological Sciences, Kogi State University, Anyigba, Nigeria. The plant leaves were rinsed in water, air dried and pulverized to fine particles. To obtain the methanol leaf extract of *Vitex doniana* (MEVd), 1000 g of the plant material were soaked in 3 litres of methanol for 48 hours. The filtration process was done using a filter paper (Whatman grade 1) and vacuum pump. The extract was concentrated at 40°C using a rotary evaporator (RV 05 basic, Germany) and water bath (HH-W420, England) to dryness. The crude extracts obtained was stored in capped vials at 4°C.

Animals

Adult male wistar albino rats of body weight ranging from 171 ± 7.86 g were obtained from the animal breeding and care facility of Federal University Lokoja, Nigeria. The animals were kept in standard rat cages at room temperature ($25 \pm 2^\circ\text{C}$) with a normal 12-hour light/dark cycle and received standard commercial pelleted rat chow and water *ad libitum*. The rats were housed in the animal house facility of Department of Biochemistry, Kogi State University, Nigeria. Handling and treatments of rats was in conformity with standard guideline for laboratory animal care and use. The rats were allowed to acclimatize for a period of 14 days.

Treatment and grouping of experimental animals

Cadmium was dissolved in distilled water and orally given to the male wistar albino rats at a dose of 10 mg/kg body weight (b.wt) (Al-Hashem *et al.*, 2009) using a feeding needle. The *Vitex doniana* extract (MEVd) was dissolved in distilled water. Cadmium was administered in groups II, III and IV.

Twenty five male Wistar rats were randomly divided into five groups of five rats each. All treatments were

done orally daily for 6 weeks. The time difference between MEVd and cadmium administration was 6 hours daily. The different dosage of MEVd adopted was to determine the more effective dose.

Group I served as control and received 1 ml distilled water. Group II received only Cadmium (10 mg/kg b.wt). Group III rats were treated with MEVd (200 mg/kg b.wt and Cadmium (10 mg/kg b.wt) at 6 hours interval daily. Group IV rats were treated with MEVd (400 mg/kg b.wt and Cadmium (10 mg/kg b.wt) at 6 hours interval daily. Group V rats received only MEVd (400 mg/kg b.wt) daily.

Animal sacrifice and collection of tissues

After 6-weeks of treatment, the rats were deprived of food overnight and the following day were anesthetized and sacrificed by jugular puncture. Immediately after the blood was collected, the liver and kidneys were quickly excised, trimmed of connective tissues, rinsed with saline to eliminate blood contamination, dried with blotting paper, weighed (so as to calculate the relative weight) and stored in 10% formalin for histological investigation.

Preparation of serum

The blood samples collected into plain sample tubes were allowed to clot and the serum separated by centrifugation at 1000 g for 15 minutes using a centrifuge (Surgifriend Medicals SM800B, England). The clear supernatant, the serum, was used for the assay of biochemical parameters.

Determination of biochemical parameters

The Serum creatinine concentration was determined according to the colourimetric method of Bartels and Bohmer (1973). The serum urea levels was determined by the method Berthelot's reaction (Fawcett and Scout, 1960). Sodium ion in serum was determined using the method of Trinder (1951) and Maruna (1958). Serum Potassium ion concentration was determined using the method of Terri and Sesin, (1958). The concentration of serum Chloride ion was determined using the method of Skeggs and Hochstrasser (1964). The determination of serum ALT and AST activities was carried out as outlined in Randox kits. The serum Total bilirubin concentration was determined according to the method described by Sherlock (1951) as outlined in Randox Kit.

Histological examination

The histopathology of the tissues of the kidney and liver of the rats was done using the method of Drury and Wallington (1980).

Statistical analysis

All data were expressed as mean \pm SD (n=5). The statistical significance was evaluated by one-way analysis of variance (ANOVA) and individual comparisons were obtained by Duncan's multiple range test (DMRT) using SPSS (V. 20.0, Chicago, USA). Values were considered statistically significant when $p < 0.05$.

Results

Percentage yield of extract

The percentage (%) yield of the methanol leaf extract of *Vitex doniana* was 8.25%.

Effect of MEVd on body weight of Cadmium administered rats

Administration of Cadmium chloride significantly ($p < 0.05$) retarded the growth (body weight gain) and increased the kidney weight of the experimental animals when compared with the distilled water treated control animals (Figure 1). However, administration of all the doses of the extract of *V. doniana* significantly ($p < 0.05$) increased the body weight and decreased the kidney weight of the cadmium chloride administered animals towards the control value. It is worthy of note that there was a significant difference ($p < 0.05$) in the body weights of the apparently normal animals that were administered only the higher dose (400 mg/kg body weight) of the plant extract when compared with the distilled water administered animals (control).

Effect of MEVd on kidney function parameters of Cadmium administered rats

Administration of Cadmium chloride significantly ($p < 0.05$) increased the urea, creatinine, K^+ , Na^+ and Cl^- concentrations in the serum of the animals when compared with the distilled water treated control animals (Table 2). The administration of all the doses of the extract significantly ($p < 0.05$) ameliorated and in some cases restored the trend of these Cadmium induced alterations in the biochemical parameters towards the control values (Table 2).

Effect of MEVd on liver function parameters of Cadmium administered rats

Furthermore, the same Cadmium administration significantly ($p < 0.05$) increased the activities of AST and ALT, and total bilirubin concentration in the

serum of the animals. The administration of all the doses of the extract significantly ($p < 0.05$) ameliorated and in some cases restored the trend of these cadmium induced alterations in the biochemical parameters towards the control values (Table 3).

Table 1: Effects of Vd on the body and kidney weight of Cadmium administered rats

Treatments	Body weight (BW)		BW gained (g)	Kidney weight (g)	Body-kidney weight ratio
	Initial BW (g)	Final BW (g)			
Control	160.66 ± 1.96	254.57 ± 22.40	92.93 ± 14	0.88 ± 0.01	289.28
Cd (10mgkg ⁻¹ b.w.)	177.21 ± 7.72	201.76 ± 6.49	24.62 ± 1.79	1.09 ± 0.01	185.10
Vd (200mgkg ⁻¹ b.w) + Cd	168.81 ± 7.73	242.27 ± 19.68	77.47 ± 8.73	0.90 ± 0.02	269.19
Vd (400mgkg ⁻¹ b.w) + Cd	166.96 ± 8.57	228.45 ± 6.89	61.49 ± 4.28	0.91 ± 0.02	251.04
MEVd (400mgkg ⁻¹ b.w) only	168.46 ± 7.32	245.57 ± 17.84	81.17 ± 9.60	0.89 ± 0.01	275.92

Table 2: Effect of *Vitex doniana* leaf extract on kidney function of Cadmium administered rats

Treatment group	Urea (mmol/L)	Creatinine (μmol/L)	K ⁺ (mmol/L)	Na ⁺ (mmol/L)	Cl ⁻ (mmol/L)
Control	2.04 ± 0.03	56.76 ± 7.38	5.43 ± 0.99	84.01 ± 2.36	66.70 ± 1.50
Cd (10 mg/kg b.w)	9.65 ± 0.09	130.79 ± 7.03	7.39 ± 1.08	159.02 ± 7.53	116.41 ± 1.04
Vd (200 mg/kg b.w) + Cd	6.48 ± 0.04	33.06 ± 2.14	3.87 ± 0.66	137.89 ± 1.23	73.67 ± 5.59
Vd (400 mg/kg b.w) + Cd	4.15 ± 0.05	32.63 ± 8.47	3.89 ± 0.89	71.78 ± 1.05	66.96 ± 7.07
Vd (400 mg/kg b.w) only	2.32 ± 0.04	60.24 ± 8.47	2.84 ± 0.43	79.43 ± 1.50	64.78 ± 6.39

Table 3: Effect of *Vitex doniana* leaf extract on liver function of Cadmium administered rats

Treatments	AST (U/L)	ALT (U/L)	Total- bil. (μmol/L)
Control	10.85 ± 1.16	4.61 ± 0.59	6.92 ± 0.13
Cd (10mgkg ⁻¹ b.w.)	52.38 ± 2.54	83.51 ± 5.34	21.98 ± 2.36
Vd (200mgkg ⁻¹ .b.w) + Cd	16.95 ± 2.39	37.51 ± 2.54	6.71 ± 0.86
Vd (400mgkg ⁻¹ b.w) + Cd	16.07 ± 1.45	26.67 ± 2.30	12.22 ± 0.37
Vd (400mgkg ⁻¹ b.w.) only	13.75 ± 2.55	5.53 ± 0.21	7.22 ± 0.84

Histopathology

Effect of MEVd on Histology of Liver and Kidney Tissues of Cd-Induced Rats

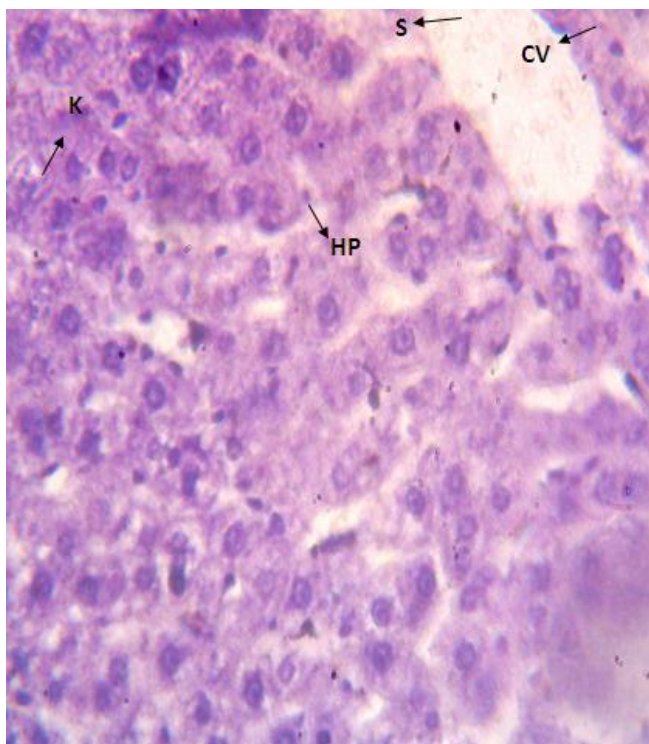


Plate 1: Cross section of liver of male rats orally administered distilled water. (H & E; mg x200)

HP: hepatocytes; K: kupffer cells; S: sinusoid, CV: central vein

Plate 1: The histology of the liver of rats administered distilled water showed normal hepatocytes, kupffer cells and sinusoid opening to the central vein, and showed normal lobular architecture.

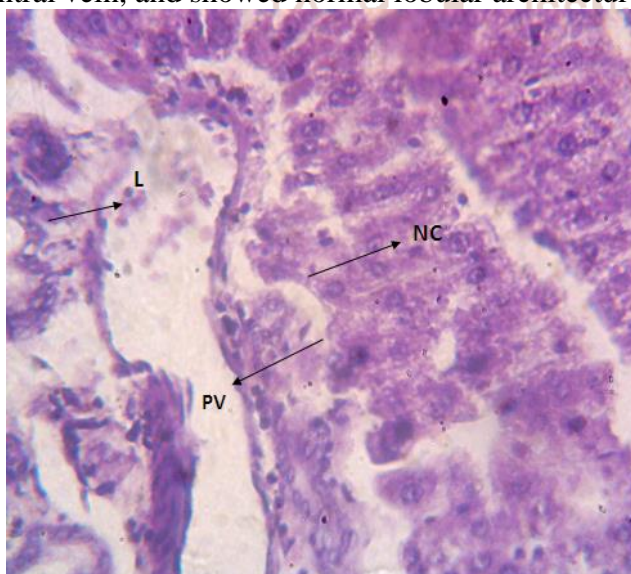


Plate 2: Cross section of liver of male rats orally administered cadmium chloride only (H & E; mg x200)

NC = Necrosis; PV = Portal vein; L = Inflammatory lymphocytes.

Histological examination at the end of six weeks (45 days) period of cadmium chloride administration caused severe liver damage including loss of hepatic architecture, necrosis and infiltration of inflammatory cells in the portal vein

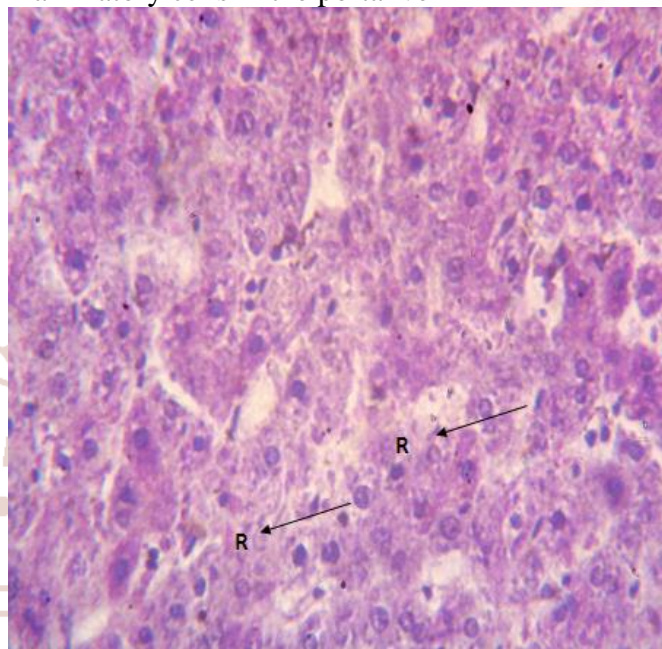


Plate 3: Cross section of liver of male rats orally administered cadmium (10 mg/kg body weight) and treated with the plant extract (200 mg/kg body weight) (H & E; mg x 200)

R = Re-epithelization

Histological examination at the end of six weeks (45 days) period of cadmium chloride administration and co-treatment with the plant extract (200 mg/kg body weight) showed restoration of the normal architecture of the liver marked by re-epithelization of the tissues.

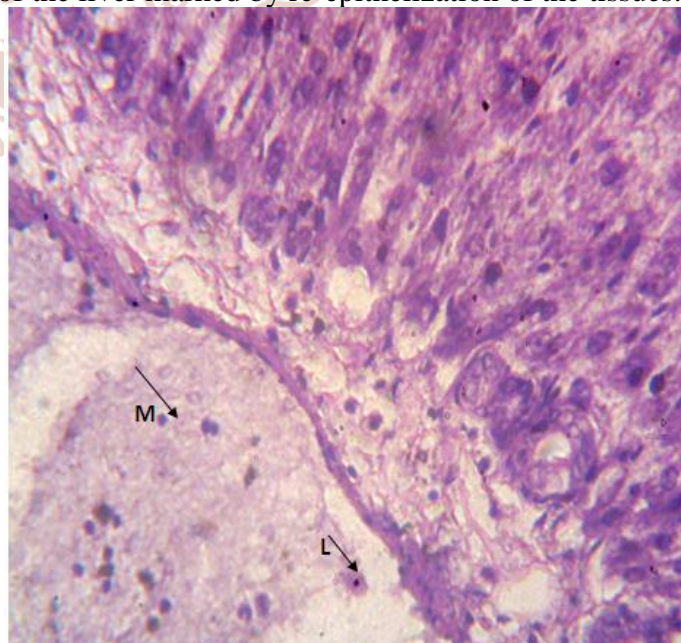


Plate 4: Cross section of liver of male rats orally administered MEVd (400 mg/kg body weight) and cadmium chloride

(H & E; mg x200)

M = Macrophages; L = lymphocytes (L)

Histological examination at the end of six weeks (45 days) period of cadmium chloride administration and co-treatment with the plant extract (400 mg/kg body weight) showed mild improvement of the architecture of the liver given the infiltration of macrophage and lymphocyte in the portal vein compared with the rats administered 1 ml distilled water (control).

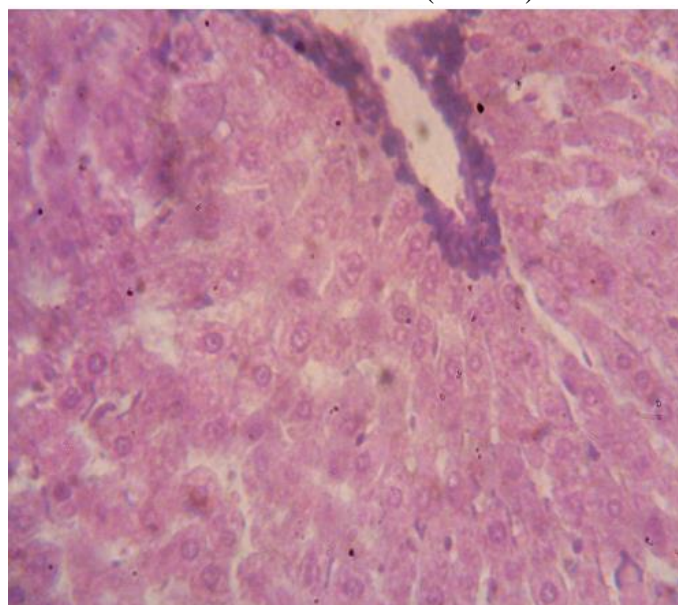


Plate 5: Cross section of liver of male rats orally administered MEVd (400 mg/kg body weight) only

(H & E; mg x200)

Section of rat liver administered 400 mg/kg body of methanol leaf extract showed normal architecture. The sinusoid leading to the central vein which is surrounded by hepatic cords radiating towards the periphery.

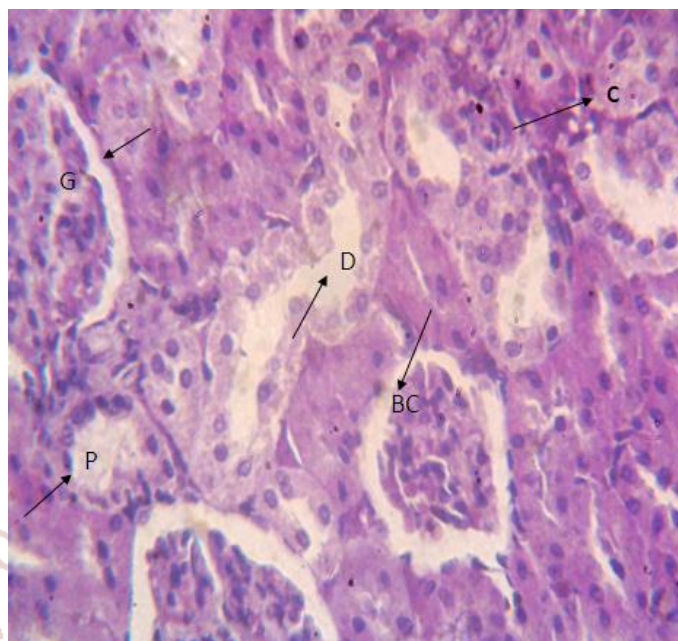


Plate 6: Cross section of kidney of male rats orally administered distilled water

(H & E; mg x200)

G = Glomerulus (G); C = Cuboidal cells; BC = Bowman's capsule; D = Distal tubule; P = Proximal tubule.

The kidney of rats administered distilled water (control) revealed the normal histological structure of the renal tissue. The renal corpuscle consisted of tuft of glomeruli (blood capillaries) surrounded by the Bowman's capsule. The renal tubules included proximal convoluted tubules, lined by large pyramidal cells with brush border and distal convoluted tubules lined by cuboidal cells.

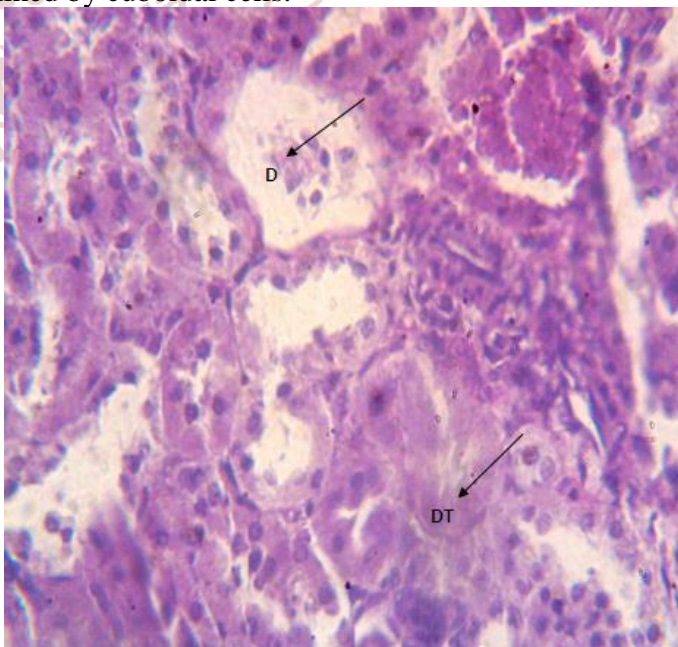


Plate 7: Cross section of kidney of male rats administered Cadmium (10 mg/kg body weight) only

(H & E; mg x200)

DT = Deletion of tubular component; P = Proximal and distal tubular necrosis; D = dissolution of tuft of glomerulus.

Histological examination of the kidney of rats at the end of six weeks (45 days) period of Cadmium chloride administration showed histopathological changes including dissolution and shrunken of tuft of glomeruli, and tubular necrosis.

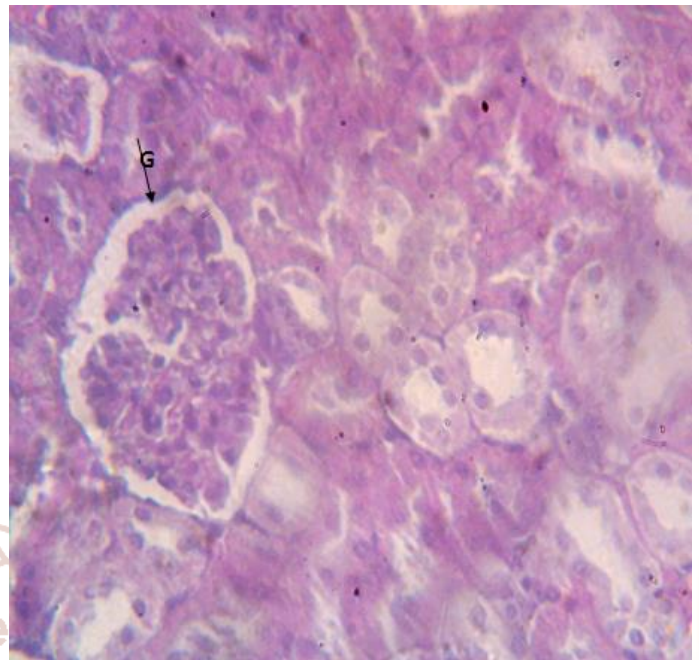


Plate 9: Cross section of kidney of male rats administered MEVd (400 mg/kg body weight) and Cadmium (10 mg/kg body weight)

(H & E; mg x200)

G = Intact glomerulus

Histological examination of the kidney of rats at the end of six weeks (45 days) period of MEVd (200 mg/kg body weight) showed that the pathological changes (dissolution and shrunken of tuft of glomeruli, and tubular necrosis) elicited by cadmium were partially reduced compared to the control.

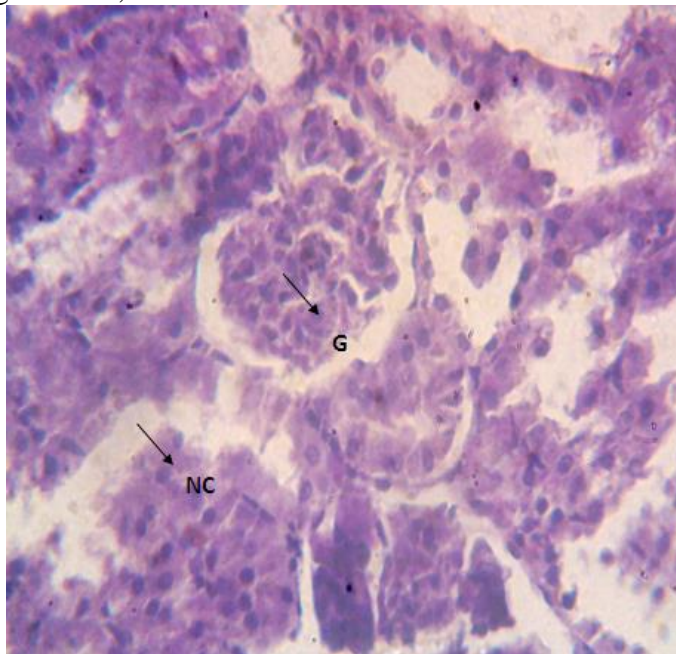


Plate 8: Cross section of kidney of male rats administered MEVd (200 mg/kg body weight) and Cadmium (10 mg/kg body weight)

(H & E; mg x200)

G = Intact glomerulus

Cross section showed that the pathological changes (dissolution and shrunken of tuft of glomeruli, and tubular necrosis) elicited by cadmium were remarkably reduced, since the glomeruli and renal tubules appeared similar to the control.

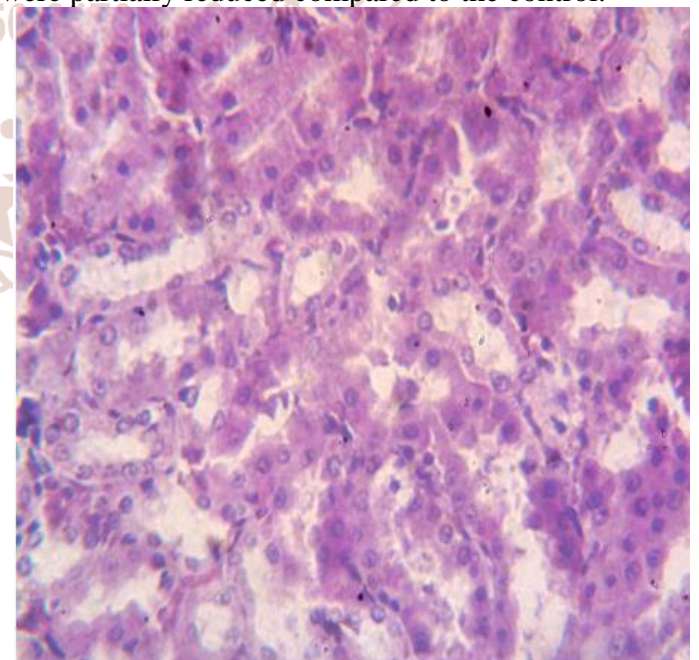


Plate 12: Cross section of kidney of male rats administered MEVd (400 mg/kg body weight) only

(H & E; mg x200)

Histological examination of the kidney of rats administered the higher dose of leaf extract of *Vitex doniana* (400 mg/kg body weight) for six weeks (45 days) period showed that the plant extract had no damaging effect on the kidney.

DISCUSSION

Numerous animal models have been developed in the past few decades for studying heavy metal induced toxicity on which the efficacy of chemical compounds including phyto-chemicals and its products as ameliorative agent(s) can be evaluated.

Cadmium is a heavy metal known for its notorious role in environmental and industrial pollution which result in deleterious effects on humans and animals. Chronic exposure to Cadmium is known to cause damage to several systems and soft tissues including the kidney and liver. However the kidney is the primary target of Cadmium intoxication (Satarug *et al.*, 2003). Therefore, the need to document agents/compounds including medicinal plants that mitigate or ameliorate this cadmium-induced toxicity cannot be overemphasized.

Six-weeks following cadmium administration, the growth (increase in body weight) of the animals was significantly retarded. Weight loss of cadmium administered rats have been linked to serum proteins reduction and severe diarrhea. It has been reported that cadmium inhibits growth (El-Demerdash *et al.*, 2004). The increase in the kidney weight of rats administered cadmium only was caused by the retarded growth and maybe hypertrophy elicited by the renal toxicity due to cadmium exposure and cadmium accumulation in the kidney (Babaknejad *et al.*, 2015). Exposure to heavy metal such as cadmium is damaging to glucocorticoids. The glucocorticoid hormones are pivotal in glucose regulation and also in carbohydrate, lipid and protein metabolism. Glucocorticoid dysfunction is associated with weight gain or loss (Ojo *et al.*, 2014)

Serum urea and creatinine concentrations are employed for estimating renal glomerular function. According to the report of Chawla (2003), elevated levels of serum urea and creatinine are associated with kidney disease. Urea is the major nitrogenous end product of protein catabolism, and the major constituent of the total urinary nitrogen excretion. For this reason serum urea and creatinine levels were assayed. In the present study, the elevated levels of

urea and creatinine by the Cadmium suggest dysfunction in the kidney by the toxic metal, also similar elevations in the serum electrolytes (Na^+ , K^+ and Cl^-) indicates adverse effects on the tubular reabsorption of the electrolytes. These effects may be associated with the changes in the threshold of tubular reabsorption, renal blood flow, and glomerular filtration rate (Ojo *et al.*, 2014). It is reported that increased serum urea concentration is an indication of reduced glomerular filtration rate in rats exposed to cadmium (Satarug and Moore, 2004). In addition, it is also proposed that Cadmium exert a direct toxicity on the glomeruli, thereby causing a decreased clearance of urea and creatinine (Noonan *et al.*, 2002). In this study, the methanol leaf extract of *V. doniana* had an ameliorating effect against cadmium-induced toxicity in kidney, as established by the significant decrease in urea and creatinine levels in the Cadmium-exposed rats co-treated with *V. doniana* compared with cadmium-alone group. The reabsorption of these biomolecules and electrolytes were facilitated by all the doses of the extract.

Increased activities of serum AST and ALT are considered to be proven indicators of hepatocellular damage. Given the antioxidant/oxidant ratio in liver cells, the levels of the hepatic enzymes, AST and ALT activities may reflect liver tissue damage maybe by a distorted cell membrane permeability which results in the leakage of the enzymes from hepatic tissue to the serum (Adefegha *et al.*, 2015). Findings from this study revealed that there was a serious necrotic hepatic damage which significantly increased the activities of AST and ALT in the serum of the cadmium intoxicated rats when compared with the normal rats administered distilled water (control group). Since the liver is the major organ responsible for the detoxification and transformation of most xenobiotics, its regulating mechanism is compromised due to accumulation of toxicants thereby leading to the tissue damage (Camargo and Martinez, 2006). The ameliorative effect of *V. doniana* on cadmium-induced hepatotoxicity may be due to the antioxidant and anti-inflammatory activities of *V. doniana* as reported by Yakubu *et al.* (2013) and Iwueke *et al.* (2006) respectively. The serum total bilirubin is also one of the major indices used to assess liver function as well as disease progression (Uthandi and Ramasamy, 2011). In this study, the elevated serum total bilirubin of cadmium administered rats was completely reversed by the oral administration of the lower dose of the leaf extract.

In all, the methanol leaf extract of *Vitex doniana* ameliorated the cadmium chloride- induced toxicity in the liver and kidney of male Wistar rats. This was evident in the significant reduction in all the elevated biochemical parameters due to cadmium toxicity and the obvious restoration of the architecture of the liver and kidney of the rats as shown in the histopathology results.

REFERENCES

- Adefegha, S. A., Omojokun, O. S. and Oboh, G. (2015). Modulatory effect of protocatechuic acid on cadmium induced nephrotoxicity and hepatotoxicity in rats *in vivo*. *SpringerPlus*, 4:619. DOI 10.1186/s40064-1408-6.
- Agbafor, K. N. and Nwachukwu, N. (2011). Phytochemical analysis and antioxidant property of leaf extract of *Vitex doniana* and *Mucuna pruriens*. *Biochemistry Research International*. 1: 1-4.
- Al-Hashem, F., Dallak, M., Bashir, N., Abbas, M., Elessa, R., Khalil, M. and Al-Khateeb, M. (2009). Camel's milk protects against cadmium chloride induced toxicity in white albino rats. *American Journal of Toxicology*, 4(3): 107-117.
- Atawodi, S. E., Bulus, T., Ibrahim, S., Ameh, D. A., Nok, A. J., Mamm N, M., and Galadima, M. (2003). *In vitro* trypanocidal effect of methanol extract of some Nigerian Savannah plants. *Afr. J. Biotech.* 2(9): 312-321.
- Babaknejad, N., Mashtaghie, A. A., Shahanipour, K., and Bahrami, S. (2015). The protective roles of Zinc and Magnesium in Cadmium-induced renal toxicity in male Wistar rats. *International Journal of Toxicology*, 8(27): 1160-1167.
- Bartels, H. and Bohmer, M. (1973). A kinetic method for measurement of serum creatinine. *Medicine Laboratory*, 26(9): 209-215.
- Burkill, H. M. (2000). Useful Plants of West Tropical Africa. Second edition, volume 5, Royal Botanic Garden Kewer, Page 272-275.
- Camargo, M. M. and Martinez, C. B (2006). Biochemical and physiological biomarkers on *Prochilodus lineatus* submitted to *in situ* test in an urban stream in southern Brazil. *Environ Toxicol Pharmacol*, 21: 61-69.
- Chawla, R. (2003). Practical clinical biochemistry: Methods and interpretation. New Delhi (India): Jaypee Brothers Publishers.
- Drury, R. A., Wallington, A. and Cameroun, S. R. (1967). In Carleton's Histological Techniques. Oxford University Press, New York. Pp 1-420.
- El-Demerdash, F. M., Yousef, M. I., Kedwany, F. S., and Baghdadi, H. H. (2004). Cadmium induced changes in lipid peroxidation, blood hematology, biochemical parameters and semen quality of male rats: protective role of vitamin E and β -caroten. *Food and chemical toxicology*, 42(10): 1563-1571.
- Fawcett, J. K. and Scott J. (1960). A rapid and precise method for the determination of urea. *Journal of Clinical Pathology*, 13(2): 156-159.
- Iwu, M. M. (1993). Handbook of African medicinal plants. CRC Press, London.
- Iwueke A V, and Nwodo O F C, Okoli C O. (2006). Evaluation of the anti-inflammatory and analgesic activities of *Vitex doniana* leaves. *Afric J Biotech.* 5(20):1929-1935.
- Jarup, L., Hellström L., Alfven T., Carlsson M. D., Grubb A., Persson B. (2000). Low level exposure to cadmium and early kidney damage. The OSCAR Study. *Occup Environ Med.* 57: 668-672.
- Maruna, R. F. L. (1958). Colorimetric determination of sodium. *Clinical Chemistry*. 2:581.
- Navaneethan, D. and Rasool, M. K. (2014). An experimental study to investigate the impact of *p*-coumaric acid, a common dietary polyphenol, on cadmium chloride-induced renal toxicity. *Food Funct* 5: 2438-2445.
- Noonan C W, Sarasua S M, Campagna D, Kathman S J, Lybarger J A, and Mueller P W (2002). Effects of exposure to low levels of environmental cadmium on renal biomarkers. *Environ Health Persp*, 110: 151-155.
- Nnamani, C. V., Oselebe, H. O and Ogbonna, A. N. (2007). Effects of leaf extracts of *Dracean aborae* L. and *Vitex donian* Sweet on the larvae of *Anopheles* mosquito. *Animal Research International*, 5(2): 184-186.
- Nwachukwu, E. and Uzoeto O. H. (2010). Antimicrobial activities of leaf of *Vitex doniana* and *Cajanus cajan* on some bacteria. *Researcher*, 2(3): 37-47.

21. Ohta, H., Yamauchi, Y., Nakakita, M., Tanaka, H., Asami, S., Seki, Y., *et al* (2000). Relationship between renal dysfunction and bone metabolism disorder in male rats after long-term oral quantitative cadmium administration. *Industr Health* 38: 339-355.
22. Ojo, O. A, Ajiboye B. O., Oyinloye B. E, Ojo A. B., and Olarewaju OI (2014). Protective effect of *Irvingia gabonensis* stem bark extract on cadmium-induced nephrotoxicity in rats. *Interdiscip. Toxicol*, 7(4): 208-1242.
23. Satarug, S., Garrett, S. H., Sens, M. A., and Sens, D. A. (2010). Cadmium, environmental exposure, and health outcomes. *Environ Health Perspect* 118: 182-190.
24. Satarug, S. and Moore, M. R. (2004). Adverse health effects of chronic exposure to low-level cadmium in foodstuffs and cigarette smoke. *Environ Health Persp*, 112: 1099-1103.
25. Satarug, S., Baker, J. R, Urbenjapol M, Haswell-Elkins M, Reilly PE, Williams DJ and Moore, M.R. (2003). A global perspective on cadmium pollution and toxicity in non-occupationally exposed population. *Toxicol Lett* 137; 65-83.
26. Sherlock, S. (1951). The liver in heart failure relation of anatomical, functional and circulatory changes. *British heart journal*, 13(3): 273-293.
27. Skeggs, L. T. and Hochstrasser, H. C. (1964). Colorimetric Determination of Chloride. *Clinical Chemistry*, 10:918.
28. Terri, A. E. and Sesin, P. G. (1958). Colorimetric Determination of Potassium. *American Journal of Clinical Pathology*, 29:86.
29. Trinder, P. (1951). Colorimetric Determination of Sodium. *Analyst*, 76:596.
30. Uthandi, A and Ramasamy K (2011). Hepatoprotective activity of Sesame meal on high fat fed Wistar rats. *International Journal of Pharmaceutical Science*, 2(12): 205-211.
31. Waisberg, M., Joseph, P., Hale, B., and Beyersmann, D. (2003). Molecular and cellular mechanism of cadmium carcinogenesis. *Toxicology* 192: 95-117.
32. Yakubu, O. E., Ojogbane, E., Nwodo, O. F. C., Nwaneri-Chidozie, V. O. and Dasofunjo, K. (2013). Comparative antioxidant and hypoglycaemic effects of aqueous, ethanol and n hexane extracts of leaf of *Vitex doniana* on streptozotocin induced diabetes in albino rats. *African Journal of Biotechnology*, 12(40): 5933-5940.

