




PEDIATRIC UROLOGY CASE REPORTS

ISSN 2148-2969

<http://www.pediatricurologycasereports.com>**Epididymo-orchitis caused by Behcet's disease: An unusual cause of acute scrotum****Hamdi Ozcan¹, Canan Ceran²**¹Department of Dermatology, Inonu University, Faculty of Medicine, Malatya, Turkey²Department of Pediatric Surgery, Inonu University, Faculty of Medicine, Malatya, Turkey**ABSTRACT**

Behçet's disease (BD) is a rare systemic inflammatory disorder of the blood vessels and tissues. It is rarely seen in children. The clinical course of the disease in children is similar to that of the adults by symptoms such as recurrent oral ulcers, genital ulcers and ocular inflammation. Additionally, urological manifestations rarely seen in BD. Here we present two children with BD and epididymo-orchitis confusing with testicular torsion. Since BD is rarely observed in children, it is very difficult to diagnose the patients with epididymo-orchitis. Treatment for the testicular torsion is immediate surgical therapy to prevent the testicular necrosis. On the other hand epididymo-orchitis caused by BD should be treated medically. Unnecessary surgery on BD patient can affect morbidity negatively. We aimed to take attention to this rare condition to prevent the patients from unnecessary operation.

Key Words: Epididymo-orchitis, acute scrotum, Behcet's disease, children.

Copyright © 2019 [pediatricurologycasereports.com](http://www.pediatricurologycasereports.com)

Correspondence: Dr. Canan Ceran,
Department of Pediatric Surgery, Inonu University,
Faculty of Medicine, Malatya, Turkey

E mail: cceran@yahoo.com

ORCID ID: <https://orcid.org/0000-0002-2014-9246>

Received 2019-01-18, Accepted 2019-02-06

Publication Date 2019-05-01

Introduction

Behçet's disease (BD) is a systemic inflammatory disorder that affects multiple organ systems, characterized by exacerbation and unpredictable time remissions. The pathogenesis of the disease is not clearly defined, but infectious agents (bacterial and viral), immune mechanisms and genetic factors are implicated in the etiopathogenesis of the disease [1]. Clinically, recurrent oral and

genital ulcers, and ocular inflammation consist of the classical triad of the BD. In addition, the patients may have joint, pulmonary, vascular, gastrointestinal, neurological and urogenital symptoms.

Usual onset of the disease is observed in between the ages of 20 to 40. However, there has been an increase in the number of the diagnosed patients with an onset before puberty because of the awareness of the disease [1,2]. The most common symptom is oral ulcers in young patients, as in adults. Epididymo-orchitis was reported in 7% of adult patients [3], and rarely reported in children. Here we are presenting two patients with recurrent epididymo-orchitis confusing with testicular torsion.

Case report 1

A 14 year-old boy was admitted to our clinic with scrotal swelling, edema and pain had been lasting for 3 days. His medical history was relevant for similar clinical symptoms occurring two years ago and he had been operated for diagnosis of testicular torsion. After the operation the surgeon was informed the family that there was no torsion, but only inflammation. He had recurrences almost every month after the operation. The boy was diagnosed as BD when he was 12 years old. Three scrotal ulcerations in addition to scrotal hyperemia, edema and tenderness was remarkable on physical examination (Fig. 1).

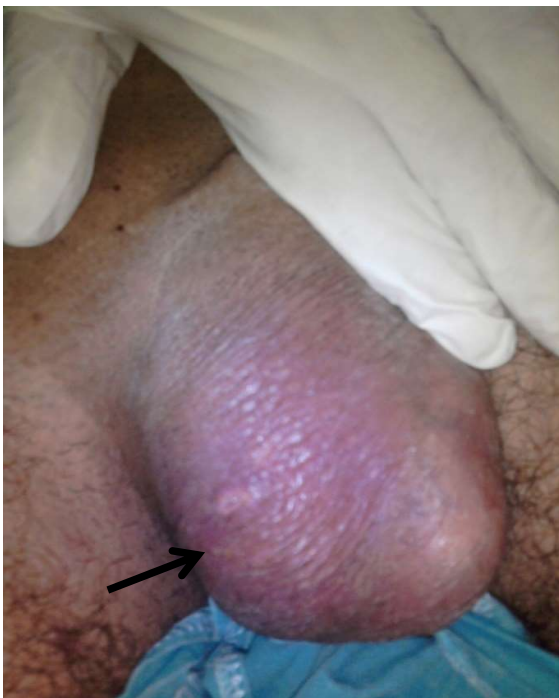

Fig. 1. Scrotal ulceration in addition to scrotal hyperemia and edema.

Ultrasonography revealed compromised blood circulation, calcifications and necrotic areas on the testes confirming the testicular torsion (Fig. 2). But we diagnosed the patient with recurrent epididymo-orchitis, a complication of BD, according to his clinical findings and medical

history. The patient was treated with systemic prednisolone and colchicine. The complaints of the patient were regressed in two days and he was discharged on fifth day of hospitalization.

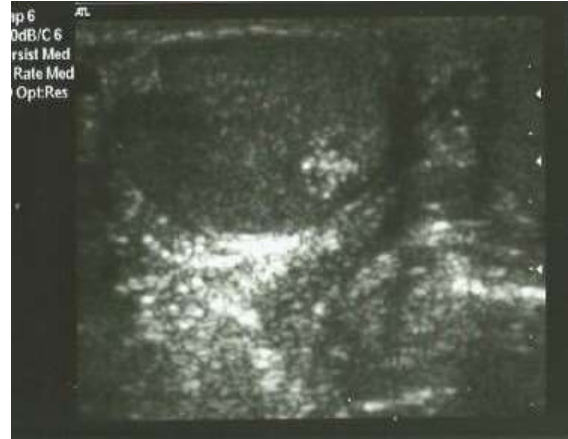

Fig. 2. Ultrasonography revealed compromised blood circulation, calcifications and necrotic areas on the testes.

Case report 2

A 12 year-old boy admitted to our clinic with scrotal pain, swelling and erythema. Ultrasonographic findings were consistent with testicular torsion. He was already diagnosed with BD, previously. He had uveitis, erythema nodosum and oral ulcers. He was treated with colchicine and steroids. Because of the BD history we considered that the patient had epididymo-orchitis. Medical treatment was adjusted and the clinical findings were regressed.

No uveitis was diagnosed on ophthalmological examination and no other systemic involvement was determined in both patients.

Discussion

Epididymo-orchitis is a clinical manifestation of Behcet's disease which has been usually neglected. The patients with BD who have

scrotal pain are usually accepted as epididymo-orchitis.

Although epididymo-orchitis (either recurrent or non-recurrent) accompanying Behcet's disease in adult patients is present in the literature, childhood cases are very rare. Kaklamani et al. [3] reported the frequency of epididymo-orchitis as 12.3 % in adults. Kirkali et al. [4] reported the incidence as 6% in Turkish adult population.

Kaklamani et al. [3] reported epididymo-orchitis frequency as 25% in their juvenile onset patients. However, only one of the seven patients had first attack at 16 years old, and the remaining six patients' first attack was seen after their 20s. They also described recurring epididymo-orchitis in five of the seven patients. According to a multicenter study in Turkey, 83 patients with juvenile onset Behcet's disease and 536 adult onset patients were evaluated the clinical findings and frequencies [1]. They did not determine epididymo-orchitis either in juvenile or adult onset Behcet's patients.

Sudden onset testicular pain with or without swelling, often referred to as the "acute scrotum," is a common presentation in children and adolescents. Testicular torsion and epididymo-orchitis are the main causes of acute scrotum. Testicular torsion is caused by twisting of the spermatic cord resulting in occlusion of the blood supply to the testis. This typically occurs spontaneously. Ultrasonography has a reported sensitivity of 63.6-100% and specificity of 97-100% for the diagnosis of testicular torsion. Although ultrasonography may reduce the number of scrotal explorations, it is operator dependent [5]. We performed ultrasonography in both patients, revealed compromised blood circulation, calcifications and necrotic areas on the testes confirming the testicular torsion.

Our first patient was operated in another clinic with the pre-diagnosis of testicular torsion. The operator stated that there was only inflammation, but no torsion. Subsequently, patient had recurring symptoms. The fact that BD was clinically present with epididymo-orchitis renders this case interesting. Previously, only one case reported in the literature, the initial symptoms of BD was epididymo-orchitis [6]. Although USG findings pointed to torsion, the previous diagnosis of BD and the recurring characteristics clinical findings directed us to make an epididymo-orchitis diagnosis. Our second patient had a medical history of BD in our clinic. Both his medical history of BD and the experience from the first case led us to an easier diagnosis. Both of the patients got better in a few days of the administration of systemic corticosteroid and colchicine treatment. Corticosteroid was discontinued after a month by tapering while colchicine therapy was carried on.

Treatment for the testicular torsion is an emergent surgery intervention. Immediate surgery might prevent the testicular necrosis. On the other hand, epididymo-orchitis caused by Behcet's disease should be treated medically. Since BD is rarely observed in children, it is very difficult to diagnose the patients with epididymo-orchitis especially if it is the presenting symptom. As case 1 presents, patients can easily be misdiagnosed with testicular torsion, which makes unnecessary surgery unavoidable. Unnecessary surgery on Behcet's disease patients can affect morbidity negatively. As a result, prior to diagnosing the patient with testicular torsion, patient needs to be checked for having clinical findings of BD, to avoid unnecessary surgery.

In conclusion, the presence of oral-genital ulcerations should be investigated in case of

epididymo-orchitis as well as other inflammatory manifestations with an unknown etiology in order to make a correct diagnosis.

Compliance with ethical statements

Conflicts of Interest: None.

Financial disclosure: None.

Consent: All photos were taken with parental consent.

References

- [1]Karincaoglu Y, Borlu M, Toker SC, Akman A, Onder M, Gunasti S, et al. Demographic and clinical properties of juvenile-onset Behçet's disease: A controlled multicenter study. *J Am Acad Dermatol.* 2008;58(4):579-84.
- [2]Krause I, Uziel Y, Guedj D, Mukamel M, Harel L, Molad Y, et al. Childhood Behçet's disease: clinical features and comparison with adult-onset disease. *Rheumatology (Oxford).* 1999;38(5):457-62.
- [3]Kaklamani VG, Vaiopoulos G, Markomichelakis N, Kaklamanis P. Recurrent epididymo-orchitis in patients

with Behçet's disease. *J Urol.* 2000;163(2):487-89.

- [4]Kirkali ZI, Yigitbasi O, Sasmaz R. Urological aspects of Behçet's disease. *Br J Urol.* 1991;67(6):638-39.
- [5]Jefferies MT, Cox AC, Gupta A, Proctor A. The management of acute testicular pain in children and adolescents. *BMJ.* 2015; 2;350:h1563.
- [6]Pektaş A, Devrim I, Beşbaş N, Bilginer Y, Cengiz AB, Ozen S. A child with Behçet's disease presenting with a spectrum of inflammatory manifestations including epididymo-orchitis. *Turk J Pediatr.* 2008;50(1):78-80.

Access this article online

<http://pediatricurologycasereports.com>

Quick Response Code

