

RESEARCH ARTICLE

Analysis of Metric Sexing Determination of Dry Hip Bones in Eastern Nepalese People

Raju K. Chaudhary¹, Santosh Kumar Deo², Sanjib K. Sah¹, Anita Thakur³, Rajneesh Jha⁴, C.P. Gaire⁵,
 Ram Lala Mallick^{5*}

¹Department of Anatomy, Birat Medical College and Teaching Hospital, Biratnagar, Nepal, India, ²Department of Physiology, Birat Medical College and Teaching Hospital, Biratnagar, Nepal, India, ³Department of OBG, Birat Medical College and Teaching Hospital, Biratnagar, Nepal, India, ⁴Department of Biochemistry, Birat Medical College and Teaching Hospital, Biratnagar, Nepal, India, ⁵Department of Biochemistry, Birat Medical College and Teaching Hospital, Biratnagar, Nepal, India

Received: 24 April; Revised: 26 May 2018; Accepted: 11 June 2018

ABSTRACT

Skeletal characteristics differ among individuals. Each population, therefore, possesses specific standards to optimize their identification accuracy. As certain features (e.g., bones of human body and enamel of tooth and skeletal) remain intact after death, these provide the precious tools for sexing of individuals in either the field of medicine or related to prehistoric osteological collections. As the sex hormones influence different reproductive function, the size-related sexual variations exist in nature remarkably. In contrast, the hip bone is an ideal bone to use for sex determination. In spite of their critical use, the findings for the determination of metric sexing with utilization of hip bones in Nepalese people still remain unknown. We, therefore, collected human hip bones and carried out the study to determination of metric sexing. Interestingly, our findings have made the present study of interest from anatomical, anthropological, and forensic points of views.

Keywords: Eastern Nepal, Hip bone, Metric sexing, Pelvis

INTRODUCTION

The appraisal of sex from skeleton using various criteria becomes important while either dealing with undocumented skeletal material in the field of medicine or work with prehistoric osteological collections.^[1-3] Skeletal characteristics vary among people. Each population, therefore, exhibits specific standards to optimization of their identification accuracy.^[4]

The percentage of accuracy for sex determination in adult bones remains 100% for entire skeleton, 98% for cranium with pelvis, 95% for pelvic bones and long bones with pelvis separately, 90–95% for long bones with cranium, 90% for cranium, and 80 % for long bones.^[5] The certain features (e.g., bones of human body, enamel of tooth, and skeletal), therefore, remain intact after death and so are valuable means that health professionals can use for sexing of individuals in either the field of medicine or related to prehistoric osteological collections.^[6]

Many bones of skeleton present the obvious size-related sexual variations to some extent.^[7] However, those of the pelvis usually display marked sex differences in morphology and exist in an independent manner to size. Such differential existence occurs in nature because, biologically, the sex hormones in addition influence different reproductive function.^[8] By contrast, the hip bones differ in two genders and reflect for special adaptation to females for child-bearing purpose. In addition, hip bones reflect to represent a number of gender-related anatomical differences.^[9,10] Hip bones, therefore, are an ideal bone for sex determination. Furthermore, the inferior border, greater sciatic notch, symphyseal surface, acetabulum, obturator foramen, and arcuate line exhibit as various components of hip bones. To study the osteometric methods of hip bones, several authors thus had paid an attention to features related to the size of this component.^[4,11,12] In spite of their critical use, the findings for the determination of metric sexing with usage of hip bones among Nepalese people still remain obscure. We, therefore, included all the above-mentioned variables under single setting to carry out the study.

*Corresponding Author:

Dr. Ram Lala Mallick

E-mail: ramlalamallick@gmail.com

Interestingly, the distinctive morphology of Nepalese human hip bones and its clear sexual dimorphism had made our study of interest from anatomical, anthropological, and forensic points of view.

MATERIALS AND METHODS

Study design and enrolment criteria

We carried out this study on dry adult human hip bones of known sex ($n = 61$) in the Department of Human Anatomy located at Birat Medical College and Teaching Hospital as well as Nobel Medical College and Teaching Hospital, Biratnagar, Nepal. Such bones, if having any congenital or iatrogenic deformity, were excluded from the present study. The instrumentations such as Sliding Caliper, Osteometric Board, and Tape were used for the measurement of hip bone dimensions.

Morphological sexing

The morphological features (such as greater sciatic notch, obturator foramen, and comparison between the diameter of acetabulum and distance of its anterior rim from pubic symphysis to ischiopubic ramus eversion) were used for sex determination. Based on these morphological features, each human hip bone was categorized into two genders: Male and female.

Metric sexing

In next, based on selecting variable by authors in their studies previously.^[4,11-13] Maximum pelvic height (MPH), maximum pelvic width (MPW), maximum pubic length (MPL), maximum ischium length (MIL), anterior superior iliac spine-pubic tubercle length (ASIS-PT), anterior inferior iliac spine-PT (AIIS-PT), ASIS-iliopubic eminence length (ASIS-IE), AIIS-IE, posterior superior iliac spine-ischial tuberosity length (PSIS-IT), and posterior inferior iliac spine-ischial spine length (PIIS-IS) maximum were selected as parameters for the determination of metric sexing on each hip bone in our study.

Statistical analysis

Data obtained from all parameters were presented as mean and standard deviations (SDs) in both the sexes. The student *t*-test was applied to find

statistical differences among various parameters, and we omitted to shown the insignificant data. The data were analyzed under Statistical Package for the Social Sciences version 16.

RESULTS

In the present study, based on features as described earlier, we carried out morphological sexing in hip bones ($n = 61$). Among these samples obtained from males ($n = 30$), we received 17 and 13 from right and left sides, respectively [Figure 1; 1st and 2nd bars from left toward right). By contrast, from the female ones ($n = 31$), we acquire 13 and 18 number of similar objects from right and left sides, respectively [Figure 2; 1st and 2nd bars].

We then determined metric sexing on each hip bone using the parameters as quoted earlier^[4,11-13] and analyzed our findings statistically depending on side and sex wise.

Side-wise (right vs. left) observations in male hip bones

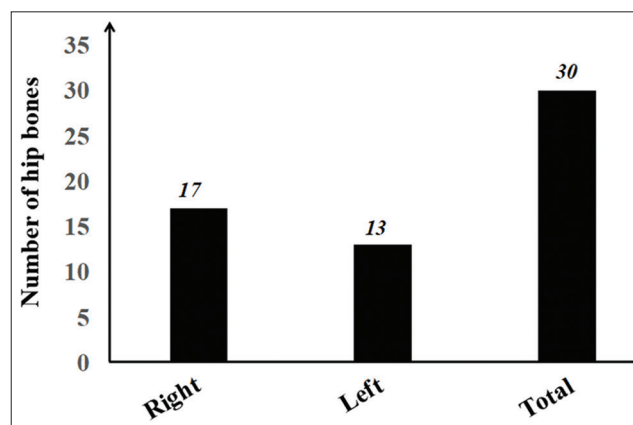


Figure 1: Sampling of male hip bones

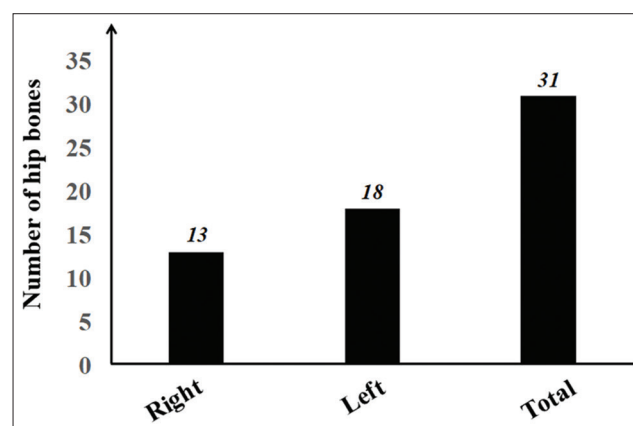


Figure 2: Sampling of female hip bones

First, we compared right side of each male hip bone with their left one to determine any possible variation among several parameters of metric sexing. The measurements were carried out in accordance with protocol as described previously.^[4,11,12] Our data demonstrated the absence of significant variation among above-mentioned variables in the right and left sides of each male hip bone [Figure 3].

Side-wise (right vs. left) observations in female hip bones

When we compared right side of each female hip bone with their left one for the investigation of change among variables of metric sexing, our findings showed the existence of a significant difference in only MPW parameter [Figure 4; 2nd pair of bars]. For determination of MPW as one of the parameters of metric sexing, we measured the straight distance from ASIS to its posterior superior one.

Gender-based (male vs. female) analysis in right-sided hip bones

We compared parameters of metric sexing in male versus female at their right-sided hip bones to find the possible variations. Interestingly, the differences were statistically significant in eight parameters of metric sexing [Figure 5 with pairs of bars having asterisk *signs]. We measured the length of hipbone dimension from the highest point of iliac crest to deepest point of IT to determine the magnitude of MPH. The mean and SD values were 19.1 ± 1.25 and 18.2 ± 0.72 cm, respectively [Figure 5; 1st pair of bars], suggesting that the difference was statistically significant with $P = 0.02$. The dimension of MPW was carried out in right-sided hip bones of males and females as mentioned above, and mean and SD values of this variable were as 14.2 ± 0.73 and 12.7 ± 0.93 cm, respectively [Figure 5; 2nd pair of bars], indicative to statistically significant difference with $P = 0.01$. For determining MPL, we measured the straight distance from midpoint of the acetabulum to the uppermost margin of pubic symphyseal surface. The mean and SD values in this parameter of metric sexing were 7.36 ± 0.47 and 7.90 ± 0.55 cm, respectively, in right-sided hip bones of males and females [Figure 5; 3rd pair of bars], so the difference was evidential with a $P = 0.05$.

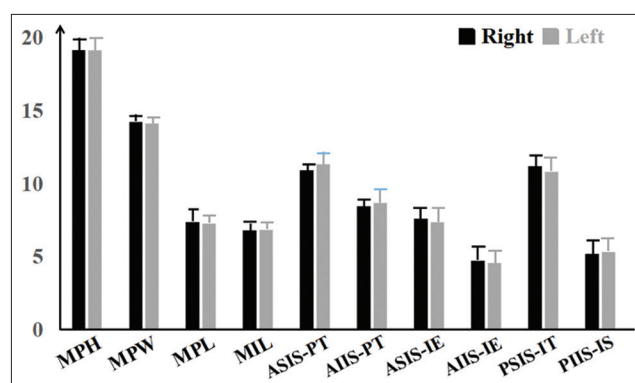


Figure 3: Bar diagram showing no significant variation in side-wise observations among parameters of metric sexing in male hip bones

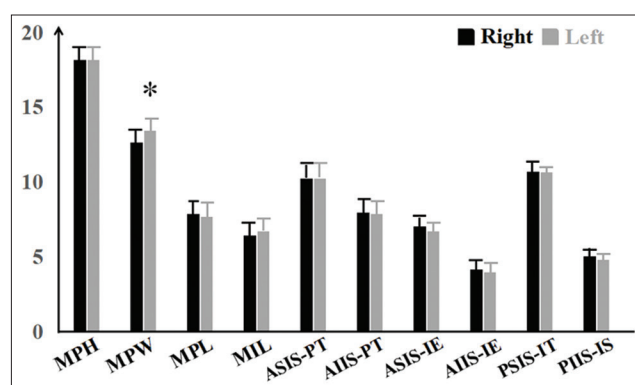


Figure 4: Bar diagram showing no significant variation in side-wise observations among parameters of metric sexing in female hip bones

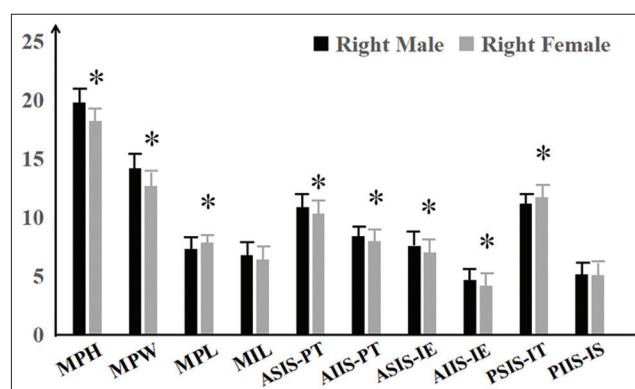


Figure 5: Bar diagram showing comparison on parameters of metric sexing in male versus female at their right-sided hip bones (* $P < 0.05$)

ASIS-PT was the next variable to be significant [Figure 5; 5th pair of bars]. The straight distance was taken between ASIS and pubic tubercle to determine ASIS-PT. The mean and SD values of ASIS-PT were 10.9 ± 0.59 and 10.35 ± 0.63 cm, respectively; the difference, therefore, was statistically significant with $P = 0.02$. Further, AIIS-PT was measured as the straight distance between AIIS and PT. We found mean and SD values of the length of AIIS-PT as 8.45 ± 0.48 and 8

± 0.67 cm, respectively [Figure 5; 6th pair of bars]; thus, the difference was statistically significant with $P = 0.04$. Then, the distance between ASIS and IE was measured for the determination of ASIS-IE. We found that the mean and SD values of ASIS-IE length were 7.58 ± 0.47 and 7.06 ± 0.78 cm, respectively [Figure 5; 7th pair of bars]; the difference is being statistically significant with a $P = 0.03$. Moreover, we measured a distance between AIIS and IE for finding the dimensions of ASIS-IE in collected each hip bones. Mean and SD values for the length of AIIS-IE length were 4.72 ± 0.43 and 4.22 ± 0.63 cm in right-sided hip bones of males and females, respectively [Figure 5; 8th pair of bars]; the difference, therefore, was statistically insignificant with $P=0.01$. Finally, in here, PSIS-IT was the significant variable in our study. PSIS-IT was measured as a distance from PSIS to IT. We observed the mean and SD values of PSIS-IT length as 11.18 ± 1.50 and 11.74 ± 1.56 cm, respectively [Figure 5; 9th pair of bars]. The difference, therefore, was statistically insignificant with $P = 0.03$.

Gender-based (male vs. female) analysis in left-sided hip bones

We then compared the variables of metric sexing in their left-sided hip bones of males and females. The mean and SD values of MPH were 19.1 ± 1.20 and 18.8 ± 1.25 cm, respectively, in left-sided hip bones of males and females [Figure 6; 1st pair of variables], indicative to significant variation with $P = 0.04$. We observed the mean and SD values of MPW parameter as 14.1 ± 0.53 and 13.4 ± 1.06 cm in their left-sided hip bones of males and females [Figure 6; 2nd pair of variables],

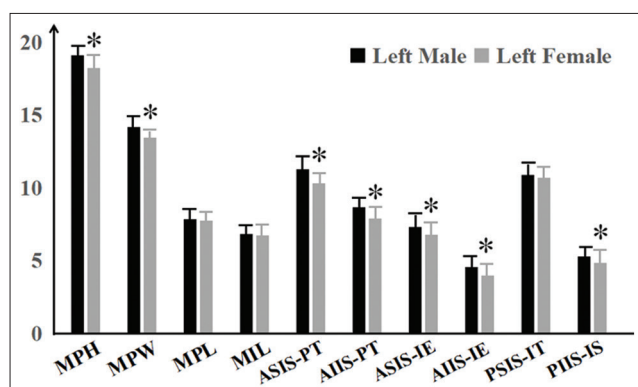


Figure 6: Bar diagram showing comparison on parameters of metric sexing in male versus female at their left-sided hip bones (* $P < 0.05$)

suggesting that the variation was statistically significant with a $P = 0.03$.

The ASIS-PT was another significant parameter of metric sexing with $P = 0.03$ in left-sided hip bones of males and females. We obtained the mean and SD values of this variance as 11.3 ± 1.01 and 10.3 ± 1.34 cm, respectively [Figure 6; 5th pair of variables]. We observed next that AIIS-IE to be significant with a $P = 0.03$ when left-sided hip bones were compared for measurement of this parameter of metric sexing between males and females as their mean and SD values were 8.56 ± 0.65 and 7.95 ± 0.85 [Figure 6; 6th pair of variables]. We found the mean and SD values of ASIS-IE length as 7.34 ± 0.68 and 6.77 ± 0.78 cm, respectively [Figure 6; 7th pair of variables]; the difference is being statistically significant with $P = 0.03$. The mean and SD values for the length of AIIS-IE length were 4.55 ± 0.72 and 4 ± 0.68 cm in left-sided hip bones of males and females, respectively [Figure 6; 8th pair of variables]; the difference, therefore, was statistically significant with $P = 0.03$. We measured the distance from PIIS to IS for the determination of the dimension of PIIS-IS. The mean and SD values were 5.3 ± 0.61 and 4.86 ± 0.77 cm, respectively, in left-sided hip bones of above two genders [Figure 6; 10th pair of variables], indicating that the difference was statistically significant with a $P = 0.09$.

Gender-based analysis in right plus left-sided hip bones

We summarized the dimensions at right- and left-sided hip bones in each parameter of metric sexing, obtained their mean values, and compared between two genders to investigate the probability of any variations. According to our findings, the differences in magnitudes of males and females were remarkable in MPH, MPW, ASIS-PT, AIIS-PT, ASIS-IE, and AIIS-IE parameters of metric sexing and other variables remained insignificant. The mean and SD values of MPH were 19.1 ± 1.17 and 18.5 ± 1.11 cm, respectively, in hip bones of males and females, respectively [Figure 7; 1st pair of bars], indicating that the variation was statistically significant with $P = 0.05$. We observed the mean and SD values of MPW as 14.1 ± 0.53 and 13.4 ± 1.06 cm, respectively, in hip bones of males and females [Figure 7; 2nd pair of bars],

indicative to statistically significant difference with a $P = 0.05$.

The mean and SD values of ASIS-PT were 11 ± 0.79 and 10.3 ± 1.12 cm, respectively, in above bones of males and females [Figure 7; 5th pair of bars]; the difference, therefore, was statistically significant with $P = 0.03$. Further, we found mean and SD values of the length of AIIS-PT as 8.67 ± 0.81 and 7.92 ± 0.98 cm, respectively; thus, the difference was statistically significant with $P = 0.03$. We also observed the statistically significant variation with $P = 0.03$ in ASIS-IE measurement between males and females as their mean and SD values were 7.34 ± 0.68 and 6.77 ± 0.78 cm, respectively. Mean and SD values for the length of AIIS-IE length were 4.60 ± 0.57 and 4.09 ± 0.65 cm in hip bones of males and females, respectively [Figure 7; 8th pair of bars]; the difference, therefore, was statistically significant with $P = 0.03$.

Side-wise analysis (right and left sides) of collected hip bones

Next, we summarized the dimensions of right-sided hip bones of males and females for each parameter of metric sexing, calculated to obtain their mean values, and compared with left side to find the probability of variations. With respect to this, AIIS-PT was the significant one with $P = 0.02$. The mean and SD values of its length were 8.25 ± 0.60 and 10.7 ± 0.97 cm, respectively, at right and left sides of hip bones [Figure 8; 6th pair of bars].

DISCUSSION

In the present study, we collected 30 male and 31 female hip bones. A total of these 61 adult

hip bones were then categorized on the basis of morphological features of greater sciatic notch, obturator foramen, and comparison between diameter of acetabulum and distance of its anterior rim from pubic symphysis to ischiopubic ramus eversion. Further, MPH, MPW, MPL, MIL, ASIS-PT, AIIS-PT, ASIS-IE, AIIS-IE, PSIS-IT, and PIIS-IS were ten morphometric variables. We measured these variants in all hip bones and analyzed statistically.

In relation to the earlier investigation on measurement of MPH, Dixit *et al.* had previously reported a $P = 0.32$ when comparisons were made between hip bones of males and females.^[4] In our study, we observed the existence of a much lesser $P = 0.05$ for MPH when male data were compared with female. The MPH findings were in addition analyzed with respect to right versus left sides and males versus females [1st pairs of bars; Figures 5 and 6]. Relatively, our result showed the significant variation with $P < 0.05$ of both right-male versus right-female and left-male versus left-female, respectively. Our findings, therefore, disagree with the findings obtained in an earlier study carried out by Dixit *et al.*, in 2005.

Further, Dixit *et al.* already reported a $P = 0.52$ for MPW when comparisons were made between male and female.^[4] In the present study, we obtained a significant $P < 0.05$ for MPW when male data were compared with female [2nd pair of bars; Figure 7]. As the previous study carried out by Dixit *et al.*, in 2005, was devoid of having a significant finding in MPW variant,^[4] the results of the present study declines to their observation. Moreover, in addition to the study carried out by Dixit *et al.*,^[4] the next study carried by the same author and others reported a remarkable $P = 0.05$

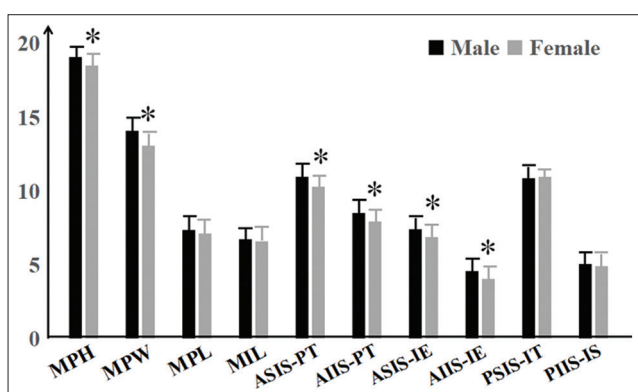


Figure 7: Bar diagram showing comparison on parameters of metric sexing in male and female hip bones (* $P < 0.05$)

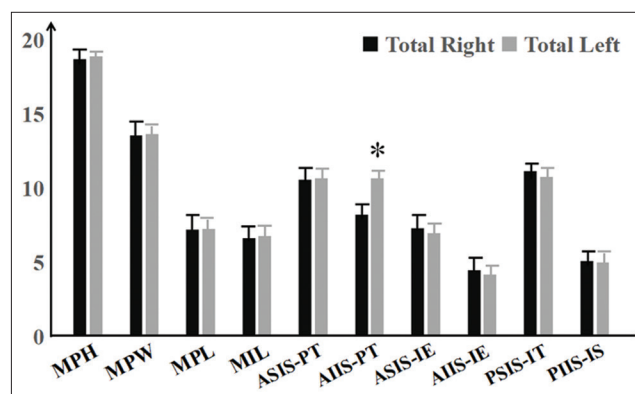


Figure 8: Bar diagram showing comparison on parameters of metric sexing in total right- and left-sided hip bones (* $P < 0.05$)

for MPL when comparisons were made between male and female.^[4,14,15] In the present study, a much lesser P values that were indicative to the level of significance were found for similar variable when male data were compared with female [3rd pair of bars; Figure 5]. As an earlier study carried out by Dixit *et al.*, in 2005, previously also obtained a significant $P = 0.05$, our results were in accordance with that. To emphasize our data relative to MPL, Thomas *et al.* had reported in their separate studies that pubic bone remains longer in females compared to males, but the difference appears after puberty.^[16] According to these separate surveys and as sex hormones biologically influence several reproductive functions in women, measurement of pubic bone stands as the best indicator for sex determination. Hence, the values obtained in the present study for MPL parameter thus supports the statement put forwarded by Thomas *et al.*^[16] Moreover, Dixit *et al.* reported a $P = 0.5$ for MIL when comparisons were analyzed between male and female^[4] Our findings tally to this result as we devoid of having any remarkable variation in numerals of MIL.

In relation to earlier investigation on measurement of ASIS-PT, Pellico and Camacho reported $P = 0.02$ and 0.67 when comparisons were done between male versus female and total-right versus total-left, respectively.^[11] In our study, we found a much lesser $P = 0.02$ for ASIS-PT when male data were compared with female [5th pair; Figure 7]. When we additionally compare ASIS-PT data in relation to total-right versus total-left, there was a lack of statistically significant differences for ASIS-PT [5th pair; Figure 8]. These results, therefore, are in agreement with that obtained from the previous study.^[11]

Pellico and Camacho, further in concern to AIIS-PT, reported the $P = 0.02$ and 0.68 when comparisons were made between male versus female and total-right versus total-left.^[11] In the present study, the remarkably equivalent P values were noted for the measurement of AIIS-PT when male data were compared with female [6th pair of bars; Figure 7] and the non-significant $P > 0.05$ for ASIS-PT when we analyzed the findings between total-right and total-left [6th pair of bars; Figure 8]. Hence, the results of present study are in agreement with that of the above study.^[11]

In addition to the findings obtained by Pellico and Camacho, moreover, several other groups had

reported the $P = 0.02$ and 0.69 for ASIS-IE when comparisons were done between male and female total-right and total-left.^[11,17,18] In the present study, an equal $P < 0.05$ was noted for ASIS-IE when male data were compared with female [7th pairs of bars; Figures 5-7] and $P > 0.05$ for similar parameter of metric sexing when comparisons were done between total-right and total-left. The results of the present study, therefore, agree to that of several previous studies.^[11,16,17]

In next, such groups of researchers reported the $P = 0.02$ and 0.89 for AIIS-IE when analyses were done between male versus female and total-right versus total-left.^[11,16,17] In the present study, an equivalent $P < 0.05$ was noted for AIIS-IE when male data were compared with female [8th pairs of bars; Figures 5-7] and a non-significant $P > 0.05$ for similar variable when scrutiny were made between total-right and total-left. Hence, our results remain in agreement with that of earlier studies.^[11,16,17] In contrast, when we compared PSIS-PT data between males and females as well as total-right and total-left, there was a lack of statistically significant differences for ASIS-PT [5th pair; Figure 8]. These results, therefore, are in agreement with that obtained from previous study.^[12]

Isaac, in 2001, reported the $P = 0.29$ and 0.16 for PIIS-IS when comparisons were made between male and female and between total-right and total-left. In the present study, statistically significant variations were devoid in all variables related to PIIS-IT. The results of the present study are in agreement with that of the results obtained separately by Pellico and Camacho and Isaac, *et al.*, at their earlier studies.^[11,12]

The studies carried out by certain scientists such as Isaac *et al.* and Dixit *et al.* are only the authors to present the documented data on morphometric parameters of hip bone in South Asian subcontinent such as among Indian population.^[4,12] However, the findings for the determination of metric sexing with the usage of hip bones among Nepalese people still had remained unknown, and the present study has elaborated it in this part of the world.

ACKNOWLEDGMENTS

This study was supported and approved to carry out by the Institutional Review Committee (IRC).

For the influence, Raju Kumar Chaudhary and Ram L. Mallick thankfully acknowledge the Institutional Board. We are further thankful to Mr. Rakesh Kumar Yadav, Lecturer, Department of Human Anatomy, Nobel Medical College and Teaching Hospital, Morang, Nepal, for his kind support in collection of human hip bones and healthy discussion relatively.

REFERENCES

- Jaroslav B. A method for visual determination of sex, using the human hip bone. *Am J Phys Anthropol* 2002;117:157-68.
- Bruzek J, Murail P. Methodology and reliability of sex determination from the skeleton. *J Forensic Anthropol* 2006. DOI: 10.1007/978-1-59745-099-7_9.
- Duric M, Rakosevik Z, Donic D. The reliability of sex determination of skeletons from forensic context in the Balkans. *Forensic Sci Int* 2005;147:159-64.
- Dixit SG, Kakar S, Agarwal S, Choudhry R. Sexing of human hip bones of Indian origin by discriminant function analysis. *J Forensic Legal Med* 2005;14:429-35.
- Krogmann WM. In the Human Skeleton in Forensic medicine. Thomas Springfield (Illinois); 1962. DOI: 10.1002/ajpa.1330200234.
- Raut RS, Hosmani PB, Kulkarni PR. Role of greater sciatic notch in sexing human hip bones. *Int J Recent Trends Sci Technol* 2013;7:119-23.
- Ingrid S, Maciej H. The difficulty of sexing skeletons from unknown populations. *J Anthropology* 2015. DOI: 10.1155/2015/908535.
- Pal GP, Bose S, Choudhary S. Reliability of criteria used for sexing of hip bones. *J Anat Soc* 2004;53:58-60.
- Nganvonpanit K, Pitakarnnop T, Buddhachat K, Phatsara M. Gender-related differences in pelvic morphometrics of the retriever dog breed. *Anat Histol Embryol* 2016. DOI: 10.1111/ah.12232.
- Wang SC, Brede C, Lange D, Poster CS, Lange AW, Kohoyda-Inglis C, *et al.* Gender differences in hip anatomy: Possible implications for injury tolerance in frontal collisions. *Annu Proc Assoc Adv Automot Med* 2004;48:287-301.
- Pellico LG, Camacho FJ. Biometry of the anterior border of the human hip bone normal values and their use in sex determination. *J Anat* 1992;181:417-22.
- Isaac B. Biometry of the posterior border border of the human hip bone: Normal values and their use in sex determination. *J Anat Soc* 2002;51:43-6.
- Singh IP, Bhasin MK. A Laboratory Manual on Biological Anthropology: Anthropometry. Delhi: Kamla-Raj Enterprises; 1989. p. 127-8.
- Mohammad S, Mohammad B, Tabbane MK, Ksheersagar DD. Sexual dimorphism in human hip bone - A review. *J Cont Med A Dent* 2015;3:4-6.
- Mukhopadhyay PP. Determination of sex from fragment of hip bone in Indian Bengali. *J Indian Acad Forensic Med* 2012;34:309-11.
- Thomas A. The sexual differences of the fetal pelvis. *Anat Physiol* 1899;33:359-80.
- Shah M, Patel S, Rathod SP, Patel SV, Pandya P, Vadgama J, *et al.* Determination of sex from the anterior border of the human hip bone. *Int J Med Sci Public Health* 2013;2:313-6.
- Kanika S, Singla RK, Kalsey G. The role of the anterior border of the hip bone in sexual dimorphism: A morphometric study in the North Indian Population. *Intl J Biomed Res* 2015;6:22-4.