

RESEARCH ARTICLE

Wound Healing activity of Leaves & roots of Pavetta Indica Linn of by using different extracts

Satkar Prasad^{1*}, Anand Chaurasiya², Ravindra Pal Singh³

¹Department of Pharmacy, Suresh Gyan Vihar University, Jaipur, Rajasthan, India, ²Department of Pharmacy, Millennium College of Pharmacy, Bhopal, Madhya Pradesh, India, ³Department of Pharmacy, Suresh Gyan Vihar University, Jaipur, Rajasthan, India

Received: 02 May 2018; Revised: 25 May 2018; Accepted: 05 Jun 2018

ABSTRACT

Pavetta indica, which is known as kankara in Hindi, is widely distributed in the greater part of India. *P. indica* is a traditional medicinal plant having for various diseases. **Objective:** The aim of the present study to evaluate the wound healing activity on different extracts (petroleum ether, chloroform, and methanol) of leaves and roots of *P. indica* Linn. in albino rats using excision and incision wound models. **Materials and Methods:** The excision and incision wounds were inflicted on eight groups, each group having six albino rates and divided one group for control, six groups for test, and one group for standard treated with povidone iodine ointment. The parameter in excision observed was wound contraction and incision model was tensile strength. **Result:** It was noted that the effect produced by the methanolic extract of *P. indica* ointment showed a significant healing in both wound models. The studies indicate that the root extracts of plant have more potent healing as compared to leaf extracts. **Conclusion:** The results further suggest that *P. indica* facilitates healing by increasing the rate and extent of wound closure and increased tensile strength in wounds subject to healing.

Keywords: Pavetta indica linn, Tensile strength, Excision, Incision wounds

INTRODUCTION

Nature was the main source of drug in ancient times, the progress and development of the human race are inseparably linked to the increasing scientific knowledge, and man has been able to obtain over the centuries. Green plants are essential for all animal life on earth since they convert solar energy into organic carbon compounds which is used as a basic energy for animals.^[1] A wound is a type of injury which happens relatively quickly in which skin is torn, cut, or punctured (an open wound), or where blunt force trauma causes a contusion (a closed wound). In pathology, it specifically refers to a sharp injury which damages the dermis of the skin. Wound infection is one of the most recurrent diseases in developing countries because of poor hygienic conditions. Wound is a break in the epithelial coherence of the skin and maybe leading by disruption of the structure and function of underlying normal tissues and may also result from

a hematoma, contusion, laceration, or an abrasion. Healing of wounds begins from the moment of injury and can be extended for varying periods of time depending on the degree of wounding, and the process of wound healing can be broadly classified into three stages: Inflammatory phase, proliferate phase, and finally, the remodeling phase which finally governed the strength and appearance of the healed tissues.^[2] Four main phases of wound healing are hemostasis, inflammatory, proliferative, and maturation phase.^[3] *Pavetta indica* Linn. belonging to family Rubiaceae is shrub. In literature, it has been reported as an diuretic activity,^[4] anti-inflammatory activity,^[5] antimicrobial activity,^[6] antidiabetic activity,^[7] analgesic activity,^[8] hepatoprotective,^[9] antioxidant activity,^[10] and anticorrosive nature.^[11]

MATERIALS AND METHODS

Plant material

The leaves and roots of the plant *P. indica* Linn. were collected from Bhopal (Vindhya herbal medicinal garden) during the month of September–

*Corresponding Author:

Satkar Prasad

Email: satkarprasad1983@gmail.com

October. The collected material is compared with the published description of the drug, and identification is verified by an acknowledged expert. The plant material was identified and authenticated by Dr. Ziaul Hasan, HOD, Department of Botany, Safia College of Science and Education Bhopal (MP), India. A voucher specimen of plant was specified as 550/Bot/Safia/14a (*P. indica* leaves) and 550/Bot/Safia/14b (*P. indica* roots).

Extraction of plant material

Extraction of plant material was done by successive solvent extraction method using various organic solvent as according to non-polar to polar.^[12] The plant material was placed inside a thimble made from thick filter paper, which is loaded into the main chamber of the Soxhlet extractor. This extractor is placed on a distillation flask containing the solvent. The Soxhlet is then equipped with a condenser, and the solvent is heated to reflux. The warm solvent vapor travels up a distillation arm and floods into the chamber housing the thimble. When the chamber is almost full, it gets automatically emptied by a siphon sidearm back down to the distillation flask. This cycle may be allowed to repeat many times so that the desired compound gets concentrated in the distillation flask. The plant material was defatted with petroleum ether (40–60°C) for about 9 h, and complete defatting was ensured by placing a drop from the thimble on a filter paper which did not exhibited any oily spot. The defatted material was removed from the Soxhlet apparatus and air-dried to remove last traces of petroleum ether. The defatted material was subjected to extraction by chloroform and ethanol as solvent. The process was carried out for about different timings for different solvents. The liquid extracts were collected in a tarred conical flask. The solvent was removed by distillation. Last traces of solvent being removed under vacuum. The extract obtained with each solvent was weighed to a constant weight, and percentage w/w basis was calculated.

Wound healing activity

Selection of model

Excision and incision wound model, using albino rats was selected for assessing the wound healing activity. This model was employed to study

the rate of wound contraction, time, and tensile strength estimation. These parameters were selected because of easy availability of albino rats and simplicity in handling them.

Selection and procurement of animals

After taking permission for animal studies from the Institutional Animals Ethics Committee (Reg No. TIT/IAEC/831/P'col/2015/35), albino rats were procured and rats of either sex weighing 150–200 g were selected, maintained at 24–28°C, housed individually with free access to food and water. The animals were left for 48 h to acclimatize to the animal room conditions. They were fed with the standard diet.

Excision wound model

In the excision wound model, rats were depicted by removing hairs at the dorsal thoracic region before wounding. Rats were anesthetized by diethyl ether before excision. Circular wound of about 2.5 cm diameter was made on depicted dorsal thoracic region of rats under aseptic conditions and was observed throughout the study. The areas of the wounds were measured (in mm²) immediately by placing a transparent polythene graph paper over the wound and then tracing the area of the wound on it (approximate area 500 mm²). This was taken as the initial wound area reading.^[13]

The rats are categorized into seven groups ($n = 6$). The animal of Group I was treated as control and only ointment base applied topically. The animals of Groups II, III and IV were treated with ointment of petroleum ether, chloroform, and ethanol leaf extract of *P. indica*, and Groups V, VI and VII were treated with the ointment of petroleum ether, chloroform, and ethanol roots extract of *P. indica*. All the samples were applied topically once daily for 16 days, starting from the day of wounding. The observations of percentage wound closure were made on 4th, 8th, 12th, and 16th, post-wounding days. The wound area of each animal was measured using tracing paper method. The percentage of wound contraction was calculated from the days of measurements of wound area.

Wound contraction

The wound contraction was calculated as percentage reduction in wound area with respect to initial wound area, while the epithelization time was noted as the number of days after wounding

required for scar to fall off leaving no raw wound behind.

Incision wound model

In the incision wound model, rats depilated by removing hairs at the dorsal thoracic region before wounding. Rats were anesthetized by diethyl ether before incision. 6 cm long paravertebral incisions were made through full thickness of skin on either side of vertebral column of the rat. The wounds were closed with interrupted sutures of 1 cm apart.^[14]

The rats are categorized into seven groups ($n = 6$). The animal of Group I was treated as control and only ointment base applied topically. The animals of Groups II, III, and IV were treated with ointment of petroleum ether, chloroform, and ethanol leaf extract of *P. indica*, and Groups V, VI, and VII

were treated with ointment of petroleum ether, chloroform, and ethanol root extracts of *P. indica*. All the samples were applied topically once daily for 10 days, starting from the day of wounding. The sutures were removed on 8th post-wounding day. The tensile strength of wounds was measured on the 10th day following continuous water flow technique.

Tensile strength in incision wound model

The tensile strength was calculated in incision wound model. On the 10th day, the rats were again anesthetized and each rat is placed on a stack of paper towel on the middle of the board. The amount of the towel could be adjusted in such a way so that the wound is on the same level of tips of the arms. The clamps are then carefully clamped on the skin of the opposite side of the skin of wound

Table 1: Percentage wound contraction in excision wound model

Area of wound closure (mm ² ±SEM)					
Groups (n)	4 th day	8 th day	12 th day	16 th day	Epithelization period (days)
I	228.20±0.92 (52.60%)	168.88±0.98 (64.28%)	120.93±1.08 (76.40%)	68.60±1.12 (84.53%)	24
II	224.17±0.92 (55.16%)	160.88±0.92 (67.82%)	102.93±0.88 (79.41%)	59.61±1.13 (88.07%)	22
III	166.86±1.42* (65.84%)	74.16±1.08* (82.14%)	28.28±0.87* (92.50%)	13.03±0.86* (96.60%)	18
IV	165.76±1.40* (66.84%)	74.36±0.98* (85.12%)	27.33±0.87* (94.53%)	11.03±0.68* (97.79%)	17
V	206.97±1.51* (58.60%)	113.80±0.89* (77.23%)	53.93±1.30* (89.21%)	22.14±0.75* (95.57%)	20
VI	160.80±1.24* (69.94%)	71.16±1.28* (86.45%)	24.18±0.78* (95.60%)	10.12±1.06* (97.64%)	17
VII	150.26±1.20* (68.84%)	40.26±1.28* (88.12%)	10.58±0.85* (94.53%)	00.00±00.00 (100%)	16

#Initial wound area approx. 500 mm². ≈ n=6 animals in each groups. #Result expressed as mean area±SEM. *P≤0.01 indicates significant when compared with control. ΨFigure in parenthesis indicates percent wound contraction. SEM: Standard error of mean

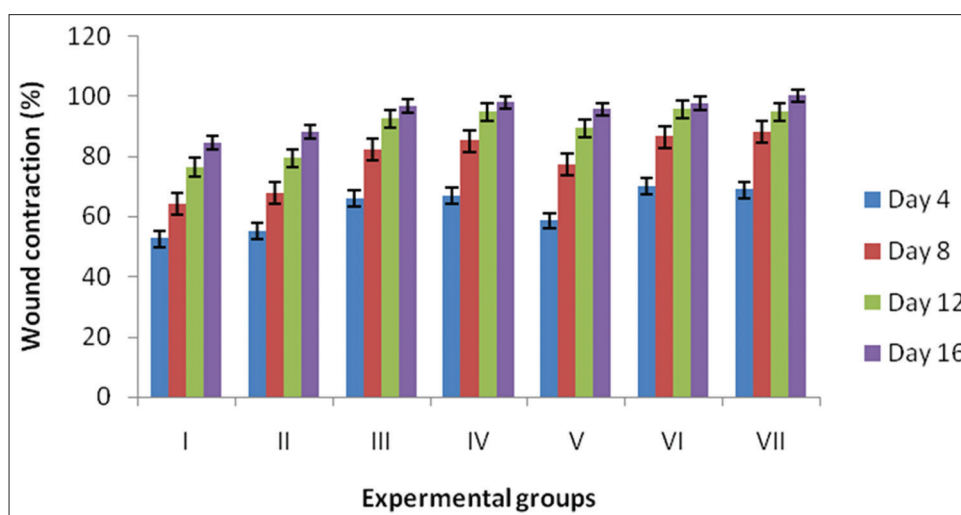


Figure 1: Excision wound healing (% wound contraction)

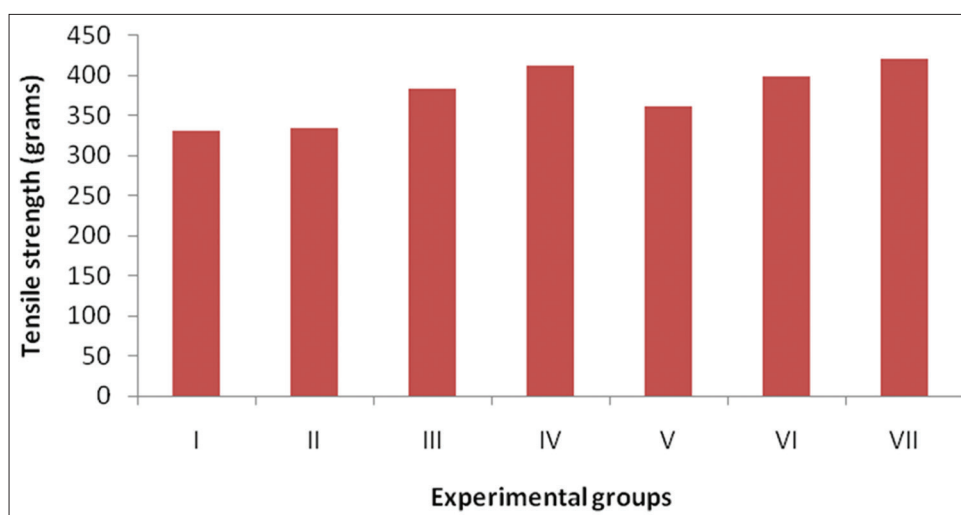


Figure 2: Incision wound healing (tensile strength)

Table 2: Tensile strength in incision wound model

Groups	Tensile strength (in g)
I	330.66±1.22
II	332.60±1.04*
III	381.66±1.20*
IV	411.16±1.13*
V	360.20±1.28*
VI	398.32±1.08*
VII	420.12±1.03*

≠Result expressed as mean area±SEM, *P<0.01 indicates significant when compared with control. SEM: Standard error of mean

at a distance of 0.5 cm away from the wound. The longer pieces of the fishing line are placed on the pulley and finally to the polyethylene bottle, and the position of the board is adjusted so that the bottle receives a rapid and constant rate of water from the large reservoir until the wound began to open. The amount of water in polyethylene bag is weighted and considered as tensile strength of the wound.^[15]

RESULT AND DISCUSSION

The studies on excision wound healing model reveal that all the seven groups showed decreased wound area from day to day. There was noticeable homogeneity in the wound contraction observed for animals in the experimental groups compared with the control group. However, on the 16th post-wounding day, animals of control group showed 84.53% of healing (which may be due to self-immunity of the animals), whereas ointment of chloroform and ethanol leaf extract of *P. indica*-treated group (III and IV) showed 96.60% and 97.79% healing. On the other hand, ointment of

chloroform and ethanol root extract of *P. indica*-treated group (VI and VII) showed 97.64% and 100% of wound healing. The end scar formed was a fine linear white scar that was visible on the flank of the animals. All readings are found to be statistically significant and comparable with control [Table 1 and Figure 1].

In incision wound model, leaf and root extract's ointment-treated group of both *P. indica* showed better tensile strength when compared with control group. *P. indica* ethanol extract's ointment-treated group showed better result [Table 2 and Figure 2].

CONCLUSION

The result of the present study showed that the wound healing activity of *P. indica* extracts for both excision and incision wound. All types of extracts of both part leaves and roots exerted wound healing activity, but root extracts (petroleum ether, chloroform, and methanol) of *P. indica* show a significant activity as compared to all leaf extract.

REFERENCES

1. Anand N. Compressive medicinal chemistry. Contribution of Ayurvedic Medicine to Medicinal Chemistry. Vol. 1. Oxford: Pergamon Press; 1990. p. 116.
2. Mohan H. Cell injury and cellular adaptation, 25. Textbook of Pathology. 4th ed. Ch. 2.
3. Blee TH, Cogbill TH, Lambert PJ. Hemorrhage associated with Vitamin C deficiency in surgical patients. *Surgery* 2002;131:408-12.
4. Ramamoorthy J, Venkataraman S, Meera R, Christina AJ, Chidambaramathan N, Devi P. Physio-Phytochemical screening and diuretic activity of leaves of *Pavetta indica* Linn. *J Pharm Sci Res* 2010;2:506-12.
5. Mandal SC, Lakshmi SM, Kumar CK, Sur TK,

- Boominathan R. Evaluation of anti-inflammatory potential of *Pavetta indica* Linn. *Phytother Res* 2003;17:817-20.
6. Gupta VK, Kaur C, Simlai A, Roy A. Antimicrobial activity of *Pavetta indica* leaves. *J Appl Pharm Sci* 2013;3:78-82.
 7. Natarajan P, Thangathirupathi A, Ramarajan S, Jaya S, Hareesh B, Laxminarayana G. Preliminary study of antidiabetic activity of methanolic extract of *Pavetta indica* Linn in diabetic rats. *Asian J Pharm Clin Res* 2013;6:131-3.
 8. Golwala DK, Patel LD, Bothara SB, Patel PM, Vaidya SK, Raval MK. Analgesic Activity of ethanolic leaf extract of *Pavetta indica*. *Int J Pharm Sci Drug Res* 2009;1:119-20.
 9. Singh NB, Saravanan N. The effect of *Pavetta indica* in ccl4 induced hepatotoxicity in rats. *Int J Compr Pharm* 2012;3:1-4.
 10. Thayyil AH, Muthu AK, Ibrahim M. Evaluation of *in vitro* antioxidant activity of various extracts aerial parts of *Pavetta indica* (Linn). *Int J Chem Pharm Sci* 2015;6:1793-8.
 11. Sheeja VN, Subhashini S. Inhibitory action of *Pavetta indica* leaf extracts on the corrosion of mild steel in acid media. *Chem Sci Trans* 2014;3:240-54.
 12. Mukherjee PK. Quality Control of Herbal Drugs. 2nd ed. New Delhi: Business Horizons; 2007. p. 2-14.
 13. Agarwal PK, Singh A, Gaurav K, Goel S, Khanna HD, Goel RK. Evaluation of wound healing activity of extracts of plantain banana (*Musa sapientum* var. *paradisiaca*) in rats. *Indian J Exp Biol* 2009;47:32-40.
 14. Muthusamy SK, Shanmugam K, Sripriya R, Praveen KS. Triphala promotes healing of infected full-thickness dermal wound. *J Surg Res* 2008;144:94-101.
 15. Lee KH. Studies on the mechanism of action of salicylate 2 retardation of wound healing of aspirin. *J Pharm Sci* 1972;57:1042-3.