

REVIEW ARTICLE

Intestinal Flagellated Giardia Lamblia: A Systematic ReviewMehrangiz Ghaffari¹, Mostafa Arabyaghoubi^{2*}¹Department of Pathology, Zabol University of Medical Sciences, Zabol, Iran, ²Department of Anesthesiology, Zabol University of Medical Sciences, Zabol, Iran**Received: 25 April 2018; Revised: 30 May 2018; Accepted: 22 June 2018****ABSTRACT**

There are four main common types of flagellated phlebotomy parasites: Giardia lamblia, Chilomastix Mesnili, Trichomonas hominis, and De Anenoba fragilis. In addition, there are also two other little tickles called Entropia hominis and retortamonas intestinalis. Except for Giardia and DeAneoba, there is no evidence of pathogenicity of other intestinal flagellated parasites. A pathogenic trichomoniasis called Trichomonas vaginalis is located in the genitourinary tract and another flagellated, called Trichomonas tenax, is found in the mouth. Searches were conducted by two independent researchers in international (PubMed, Web of Science, Scopus, and Google Scholar) and national (SID and Magiran) databases for related studies from the inception of the databases to September 2017 (without time limitation) in English and Persian languages. To ensure literature saturation, the reference lists of included studies or relevant reviews identified through the search were scanned. The detection of the parasite is done to find the trophozoites in the fluids in the duodenum by intubating or inserting the yarn into the duodenum (enterostate) or duodenal biopsy. In addition, giardiasis can be used to determine the presence of parasites in fecal samples by ELISA or immunofluorescence, or by searching for antigens of Giardia in the stool by counterimmunoelectrophoresis, ELISA, and enzyme immunoassay.

Keywords: Flagellated giardia lamblia, Giardia lamblia, Giardiasis, Intestinal**INTRODUCTION**

There are four main common types of flagellated phlebotomy parasites: Giardia lamblia, Chilomastix Mesnili [Figure 1], Trichomonas hominis, and De Anenoba fragilis. In addition, there are also two other little tickles called Entropunashominis and Retratoamonasinistinalis. Except for Giardia and DeAntenauba, there is no evidence of pathogenicity of other intestinal flagellated parasites. A pathogenic trichomoniasis called Trichomonas vaginalis is located in the genitourinary tract and another flagellated, called Trichomonas tenax, is found in the mouth.^[1] With the exception of De Anenaba, the rest of the flagstones are easily recognizable with their particular quick movement, and three larger ones can be easily identified in clean, unpainted samples prepared in saline. The tri-chromium method is superior to hematoxylin for colorizing the flagellates. Cytoplasmic

filamentous structures in these creatures, which usually have a diagnostic value, are better seen by staining with trichromium.^[2]

MATERIALS AND METHODS**Search strategy**

Searches were conducted by two independent researchers in international (PubMed, Web of Science, Scopus, and Google Scholar) and national (SID, Magiran) databases for related studies from the inception of the databases to September 2017 (without time limitation) in English and Persian languages. To ensure literature saturation, the reference lists of included studies or relevant reviews identified through the search were scanned. The specific search strategies were created by a Health Sciences Librarian with expertise in systematic review search using the MESH terms and free terms according to the PRESS standard. After the MEDLINE strategy was finalized, it was adapted to search in other databases. Accordingly, PROSPERO was searched for ongoing or recently

***Corresponding Author:**

Mostafa Arabyaghoubi

Email: tahghhatt1@gmail.com

related completed systematic reviews. The key words used in the search strategy were “giardiasis, giardia lamblia, flagellated giardia lamblia, intestinal” which were combined with Boolean operators including AND, OR, and NOT.

Study selection

Results of the literature review were exported to endnote. Before the formal screening process, a calibration exercise was undertaken to pilot and refine the screening. Formal screening process of titles and abstracts was conducted by two researchers according to the eligibility criteria, and consensus method was used for solving controversies among the two researchers. The full text was obtained for all titles that met the inclusion criteria. Additional information was retrieved from the study authors to resolve queries regarding the eligibility criteria. The reasons for the exclusion criteria were recorded. Neither of the review authors was blinded to the journal titles, the study authors, or institutions.

DISCUSSION

Giardia lamblia

Giardia trophozoites live in the upper intestine, where they are in close contact with the mucosa. They may penetrate down the inside of the mucous membrane and there might sometimes be found in the gallbladder and biliary secretions.^[3] The upper portion of the abdominal surface has been

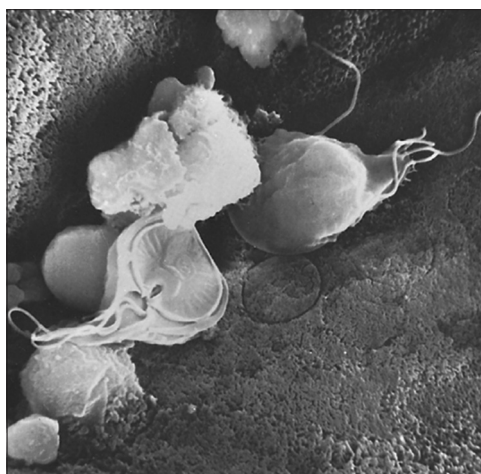


Figure 2: Scanning electron micrograph of Giardia showing sucking disk and flagella; imprints of sucking disks are seen on the surface of intestinal mucosa (courtesy of Dr. Robert L. Owen, San Francisco, CA.)

altered to create a suction plate. This plate causes the parasite to attach to the intestinal wall and, depending on the binding rate, can stimulate the intestinal tissue mechanically. Photomicrography with electron scanning electron microscopy from the intestinal mucosa of giardia shows a convincing evidence of such damage [Figure 2].^[4] Giardia's attachment to the duodenal mucosa [Figure 3] may be facilitated by a kind of lectin produced by the parasite activated by a duodenal discharge.^[5]

Giardia is easier to detect than any other intestinal protozoa. Its trophozoite has a double-sided symmetry, and its interior structures are paired together.^[6]

Like de enanthoba, trophozoites have two nuclei. The length of the parasite is 9–21 and the width is 5–15 μm . It moves slowly, rotating, and with a twist around a longitudinal axis. This type of movement is similar to moving a falling leaf. When the parasite is seen, it looks pear-shaped. The anterior part is narrow and the posterior section, too, is narrow. Giardia trophozoites have four flagella paws: Two in the anterior, two in the side, two in the abdomen, and two in the back. Both nuclei are located in the sucker area and in the anterior part of the body. Two curved bars are also seen at the bottom of the suction plate.^[7] These rods are called midts, which are the characteristics of this protozoan. The curved sections in the cytoplasm of the anterior flagella are called exon. Tail exons are not curved; they are straight, in close proximity, and parallel to each other; they divide the parasite from the longitudinal direction into two halves. The nuclei are round or oval, each with a large central karyosome. There is no peripheral chromatin.^[8] In unstained trophozoites,

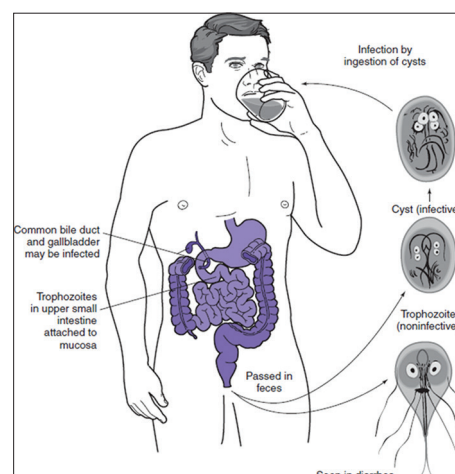


Figure 3: Lifecycle of Giardia lamblia

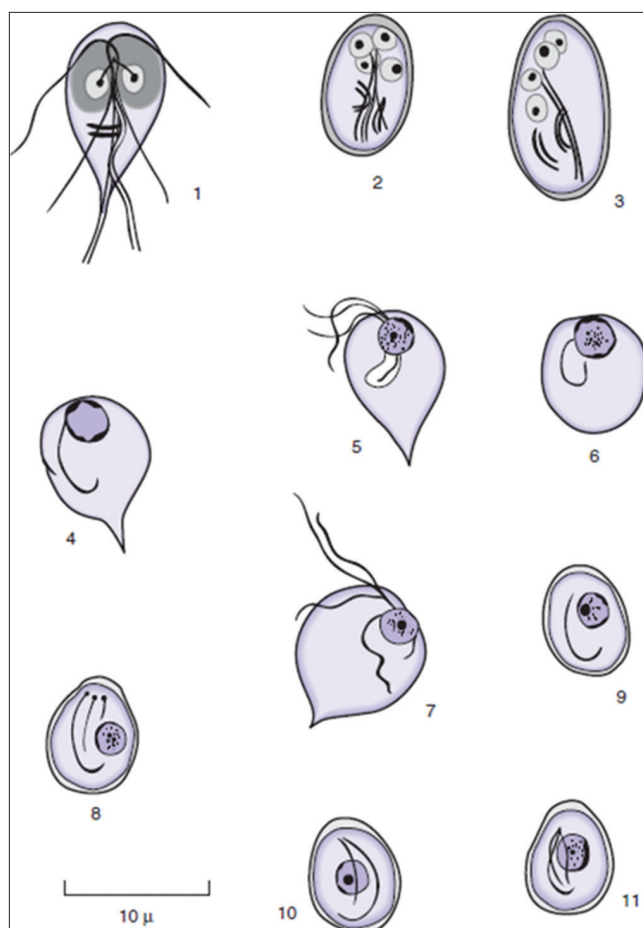


Figure 1: 1, *Giardia lamblia* trophozoite; 2, 3, *G. lamblia* cysts; 4, 5, 6, 7, *Chilomastix mesnili* trophozoites showing variation in structural detail, which may be seen in permanent; 8, 9, 10, 11, *C. mesnili* cysts (3, 4, 6, 7, 9, 10, and 11 show diagnostic features only)

the shape of the body, its specific movement, and sometimes some flagellates are seen. In samples, stained with stable colors, the shape of the body of the parasites, nuclei, axoneme, and middle bodies are observed.^[9] The cysts are oval and their size is 8–14 at 10–7 µm. Although intermediate nuclei and objects can be seen in live parasites, the addition of iodine di Anthony makes these structures more visible. Sustained staining of cysts, four distinct nuclei, middle cortex, other dual structures and cytoplasmic segments, and unconscious flagellates are observed within the cyst. The wall of the cyst is smooth and stainless and is usually far from the cytoplasm due to the cytoplasmic collapse during staining for coloring. *Giardia* cysts are colored green to red if they are stained with trichrome. Its internal structures may appear in reddish browns in a green background.^[10] *Giardia* does not appear permanently in the stools of infected patients. Three types of parasite are described; first, severe, where the parasite exists in almost all stool specimens;

second, mild, where the parasite is found in only 40% of samples; and third, mixed type, in which case the patient experiences intense excretion of the parasite in three subsequent weeks followed by disposal of small amounts of parasite.^[11] Thus, it is necessary to collect specimens of the feces that are negative for parasitism at intervals of several days. Furthermore, the detection of the parasite is done to find the trophozoites in the fluids in the duodenum by intubating or inserting the yarn into the duodenum (enterostate) or duodenal biopsy. In addition, giardiasis can be used to determine the presence of parasites in fecal samples by ELISA or immunofluorescence, or by searching for antigens of *Giardia* in the stool by Kattraymvnvalktrvfrz (CIE), ELISA, and enzyme immunoassay.^[12] Followings are the main characteristics of *Giardia lamblia*.

| | |
|----------------------------|--|
| I. Trophozoites, unstained | Suggestive: progressive, "falling leaf" motility; pear-shaped body with attenuated posterior end |
| II. Trophozoites, stained | Diagnostic: nuclei in the area of a sucking disk; the two median bodies posterior to the sucking disk; typical arrangement of axonemes |
| III. Cysts, unstained | Suggestive: ovoid body shape, numerous refractile threads in cytoplasm |
| IV. Cysts, stained | Diagnostic: four nuclei; four median bodies; jumble of axonemes |

REFERENCES

- Morrison HG, McArthur AG, Gillin FD, Aley SB, Adam RD, Olsen GJ, *et al.* Genomic minimalism in the early diverging intestinal parasite *Giardia lamblia*. *Science* 2007;317:1921-6.
- Hill DR, Nash TE, Lamblia G. Principles and practice of infectious diseases. *Clin Microbiol Rev* 2007;2:2888-92.
- Wolfe MS. Giardiasis. In: *Netter's Infectious Diseases*. Philadelphia, PA: Elsevier/Saunders; 2012. p. 458-62.
- Halliez MC, Buret AG. Extra-intestinal and long term consequences of *Giardia duodenalis* infections. *World J Gastroenterol* 2013;19:8974.
- Roxström-Lindquist K, Palm D, Reiner D, Ringqvist E, Svärd SG. *Giardia* immunity—an update. *Trends Parasitol* 2006;22:26-31.
- Nkrumah B, Nguah SB. *Giardia lamblia*: A major parasitic cause of childhood diarrhoea in patients attending a district hospital in Ghana. *Parasites Vectors* 2011;4:163.
- Cacciò SM, Ryan U. Molecular epidemiology of giardiasis. *Mol Biochem Parasitol* 2008;160:75-80.
- Leber AL, Novak-Weekley S. Intestinal and Urogenital Amebae, Flagellates, and Ciliates. In: *Manual of Clinical Microbiology*. 10th ed. Washington, DC: American Society of Microbiology; 2011. p. 2149-71.
- Poxleitner MK, Carpenter ML, Mancuso JJ, Wang CJ, Dawson SC, Cande WZ. Evidence for karyogamy and exchange of genetic material in the binucleate intestinal parasite *Giardia intestinalis*. *Science* 2008;319:1530-3.
- Eissa MM, Amer EI. *Giardia lamblia*: A new target for

- miltefosine. Int J Parasitol 2012;42:443-52.
11. Weiland ME, McArthur AG, Morrison HG, Sogin ML, Svärd SG. Annexin-like alpha giardins: A new cytoskeletal gene family in *Giardia lamblia*. Int J Parasitol 2005;35:617-26.
 12. Pathuri P, Nguyen ET, Ozorowski G, Svärd SG, Luecke H. Apo and calcium-bound crystal structures of cytoskeletal protein alpha-14 giardin (annexin E1) from the intestinal protozoan parasite *Giardia lamblia*. J Mol Biol 2009;385:1098-112.